

CASE STUDY

Use of Innovative Allograft Bone Wedges for Treatment of Flexible Flatfoot Deformity



Surgeon Author: Thomas J. Chang, DPM.

Professor and Past Chairman of the Department of Podiatric Surgery at the California College of Podiatric Medicine. Private Practice – Redwood Orthopedic Surgery Associates, Santa Rosa, CA.
Faculty – The Podiatry Institute.

FEATURED PRODUCT: PRESERVE™ Evans Lateral Column Lengthening Allografts

PRESENTATION

12 y.o. male presents with increasing pain in both arches and flatfoot collapse. His dad also relates similar symptoms in his teenage years and wants to be proactive in seeking advice for his child. Patient has been in orthotics for the past 3 years with some mild relief. He is starting to have arch pain consistently while active, and is less excited about participating in sports lately.

EXAMINATION

Exam is essentially remarkable for a flexible collapsing flatfoot deformity. Clinically, there is transverse plane abduction noted within the midfoot / hindfoot (Fig. 1 & 2). With the subtalar joint held in neutral position, it is not possible to stabilize or lock the midtarsal joint along the lateral column. The heel rests at 4 degrees of valgus and there is moderate supinatus within the medial column. There is limitation of ankle movement to perpendicular with the knee extended; with knee flexion, he can get up to 5 degrees. Due to the patient's flexibility and his planes of compensation, it was decided to perform an Evan's Osteotomy, a Cotton Osteotomy, and a gastrocnemius lengthening.

INTRODUCTION

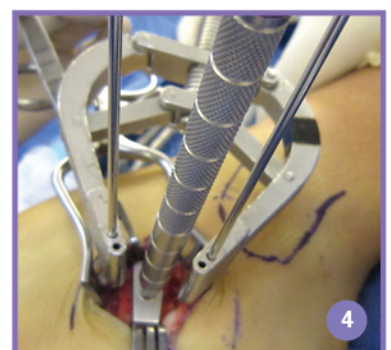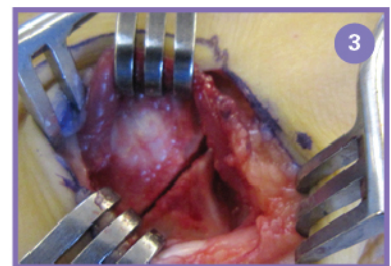
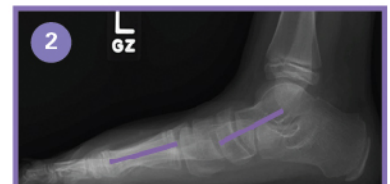
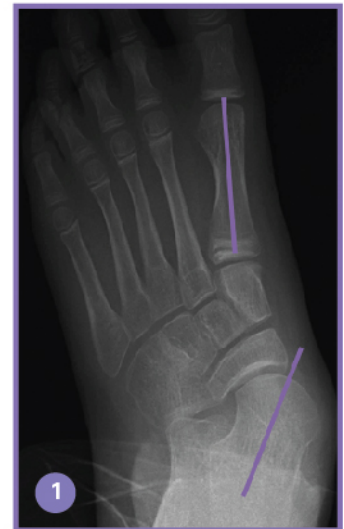Flatfoot deformities are present in all age groups. They can present with flexible to more rigid deformities. A younger patient usually exhibits more flexibility early on and this can become more rigid as time progresses. Joint adaptation and tendon imbalance can bring on more rigid deformities as patients age and become heavier. Coalitions in the hindfoot can also create rigidity at an early age.

Flexible deformities usually are treated with extra-articular procedures: soft tissue tendon work, calcaneal osteotomies, and arthroeresis. Rigid deformities usually require arthrodesis to adequately re-align the foot back underneath the leg. These can range from isolated arthrodesis to double arthrodesis and up to triple arthrodesis.

SURGICAL TECHNIQUE

Patient can be supine for all these procedures. The gastrocnemius release is performed with external rotation of the leg. A 2-3 cm linear incision is made along the posterior medial aponeurosis and then linear dissection through the deep fascia and the paratenon. The aponeurosis is released 25% at a time from medial to lateral until adequate ankle ROM is achieved.

A second incision is made over the anterior calcaneal body. The peroneals are retracted plantarly and the EDB muscle belly is raised dorsally. It is important to preserve the entire joint capsule of the CC joint to maintain stability of the anterior fragment after graft placement. A K-wire can be placed across the CC joint if preferred to keep the joint stable during distraction and graft placement. An osteotomy is now made roughly 1 cm posterior to the CC joint (Fig. 3), parallel to the joint space. A small joint distractor is used to distract out the osteotomy and lengthen the lateral column.



SURGICAL TECHNIQUE - continued

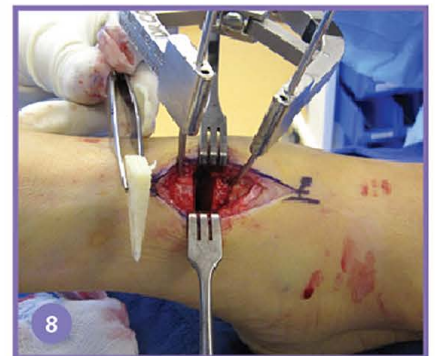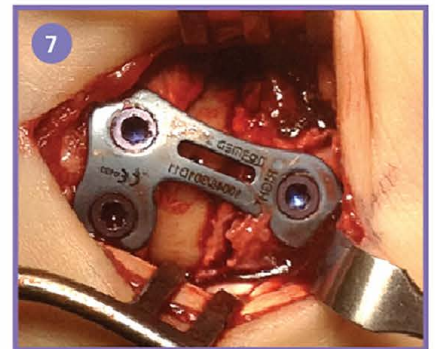
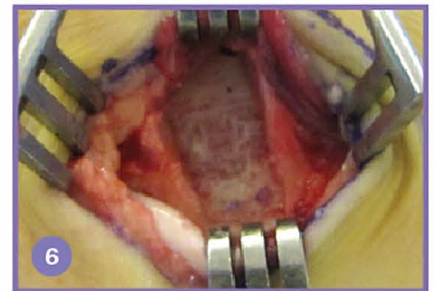
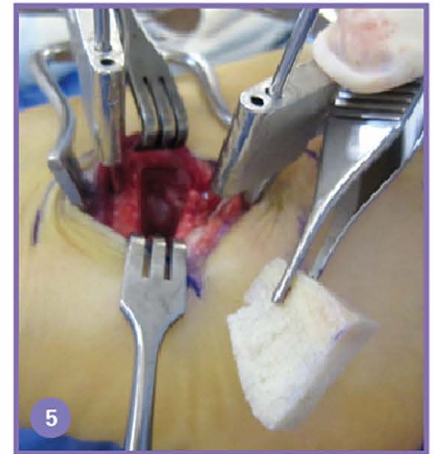
The foot is evaluated to see if adequate correction is achieved and stability is provided back to the medial and lateral columns. Intra-operative imaging may also be helpful to confirm realignment of the TN joint on the AP view. The PRESERVE™ Bone Grafts range from 6-12 mm for adequate correction. Use of the Paragon 28® trial sizers can facilitate selection of the proper graft size (Fig. 4).

The PRESERVE™ Evans Lateral Column Lengthening allografts are specifically tapered both from lateral to medial and dorsal to plantar for anatomic considerations (Fig. 5 & 6). These will allow for appropriate lengthening of the lateral column while minimizing stress to the plantar ligaments, the spring ligament and the anterior bone fragment. Use of fixation is surgeon's preference. If fixation is preferred, the HEvans™ plate has been designed by Paragon 28® specifically for the Evans procedure which offers a low profile, ramped portion for the peroneal tendons and locking screw stability of the anterior fragment (Fig. 7).

The Cotton is now performed with a linear dorsal incision over the medial cuneiform. Dissection is carried through the deep fascia medial to the EHL tendon. Joint distraction and use of the Paragon 28® trial sizers can once again facilitate selection of the proper PRESERVE™ Cotton Plantarflexing Osteotomy allograft (Fig. 8). Use of fixation is again surgeon's preference.

POST-OPERATIVE PROTOCOL

The patient is placed in a Jones compression dressing after surgery. The grafts show predictable stability usually by six weeks. He is managed for 6 weeks NWB and then transitioned into a fracture walker with physical therapy. The final clinical picture at one year shows good alignment of the left foot and continued collapse of the right side (Fig. 9). At one year, the AP radiograph shows excellent consolidation of both graft sites and stable alignment of the midtarsal joint (Fig. 10). The talo-1st metatarsal angle appears to be rectus. The lateral x-ray shows excellent restoration of the talo-1st metatarsal angle as well (Fig. 11). The hindfoot appears neutral and the first ray elevatus has been reduced nicely with the Evans / Cotton combination. Similar procedures are planned for the right foot.

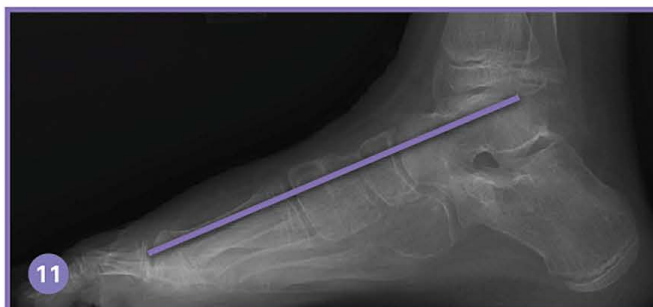
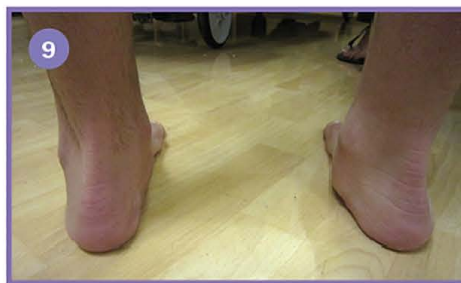
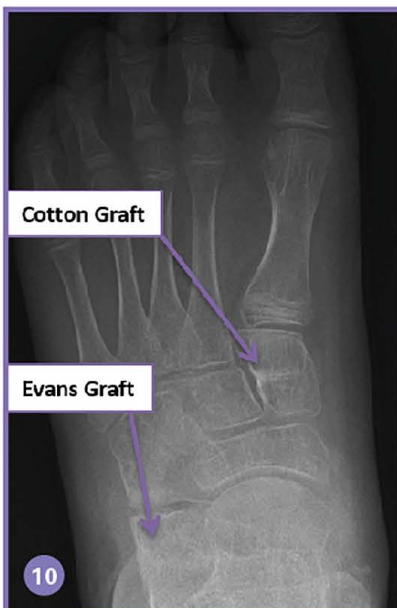
Exclusively foot & ankle
Paragon²⁸

Paragon 28, Inc.
4B Inverness Ct. E, Ste. 280
Englewood, CO 80112, U.S.A.
855.786.2828 | www.paragon28.com

P01-CS-0003 RevB
™ Trademarks and © Registered Marks of Paragon 28, Inc.
© Copyright 2016 Paragon 28, Inc.
All rights reserved.
Caution: U.S. Federal Law restricts this device
to sale by or on order of a physician.
Patents: www.paragon28.com/index.php/patents

CE 2797



Paragon²⁸