



Mgnum[™]BVF

White Paper

Exclusively foot & ankle **20**
Paragon[®]

Rabbit Femur Bone Healing Histomorphometric Evaluation

Summary – Bone void fillers are commonly used in orthopaedic surgery to help address a variety of indications. Graft substitute materials are available in a variety of formulations each with inherent benefits. This study illustrates the resorption of a Magnesium and a Calcium based materials. It was observed that:

- Resorption of Mgnum[™] was 83.3% greater at 12 weeks and 35.6% greater at 26 weeks than a calcium-based bone void filler
- Over 80% of Mgnum[™] was resorbed by 26 weeks

Objectives– This study was designed to determine the percent area of drill holes filled with residual bone void filler, bone or absence of either (“other”) in a study in rabbits testing two bone void filler products at two different time points, 12 and 26 weeks. Two bone void fillers were identified:

- Test product (Magnesium-based)
- Control product (Calcium- based)

Methods – Histological sections were provided by NAMSA (Northwood, OH) representing the left and right distal femurs of 8 rabbits at 12 weeks of healing and 8 rabbits at 26 weeks of healing. Sections were taken through the longitudinal plane of a 4mm drill hole in each distal femur and serial sections stained with Masson’s Trichrome and Toluidine Blue. For histomorphometric evaluations, sections stained with Masson’s Trichrome were used. The area of the drill hole was apparent due to its location, marker pin (in many but not all specimens), shape of the defect, presence of filler material and the modeling of adjacent bone. This area was examined under 40X magnification using a 10 x 10mm ocular grid. At 40X magnification, this grid represented 0.25 x 0.25mm superimposed on the image. The counting was performed within the area of surgically created drill hole (4mm hole diameter = 16 grid widths) with an assumption that each section was cut at the center of the drill hole. The depth of each drill hole was estimated by appearance of the bone at the periphery of the drill hole. If the end of the drill hole was not distinct, the depth was assumed to be 6mm (approx. 24 grid widths). The percent of bone, filler and “other” was determined by point counting. “Other” included mostly fatty marrow and loss of filler material without presence of replacement tissue, and least commonly, vascular tissue. For this technique the tissue or material present at each intersection of grid lines was determined through the microscope and then entered as a single count for that tissue type or presence of material. Because the depths of drill holes varied between femurs, the ratio of each tissue component over the total area was calculated and expressed as a percent.

Several standard assumptions were made for this study:

1. The original drill hole was filled with the assigned filler at the beginning of the study.
2. The area of the original drill hole that was filled at 12 or 26 weeks with tissue other than filler material replaced the filler and represented the percent filler resorption by the equation [original area expressed as points - residual filler area expressed as points x 100].
3. The error associated with sectioning would be randomly and equally distributed among the limbs and rabbits.

Results – Histologic sections from rabbit No. 49449 were excluded from evaluation due to a changed label and subsequent uncertainty of assignments. Mean percent distribution of filler, bone and other tissue type within the original drill hole at 12 and 26 weeks of healing are shown in Figure 1. The mean percent filler resorption (\pm SEM), calculated as the area of the original drill hole minus the area of the remaining filler, at 12 and 26 weeks of healing are shown in Figure 2. Filler resorption was 83.3% greater at 12 weeks and 35.6% greater at 26 weeks for the Test product compared to the Control product. ($p = 0.00016$ and $p = 0.025$, respectively). Over 80% of Test product was resorbed by 26 weeks compared to over 60% resorption of the Control product. Both fillers were replaced by either woven or lamellar mineralized bone of normal morphology, fatty marrow, or “empty space” presumed occupied by low protein fluid.

Histomorphometric Study (NAMS 06T-26537-06)

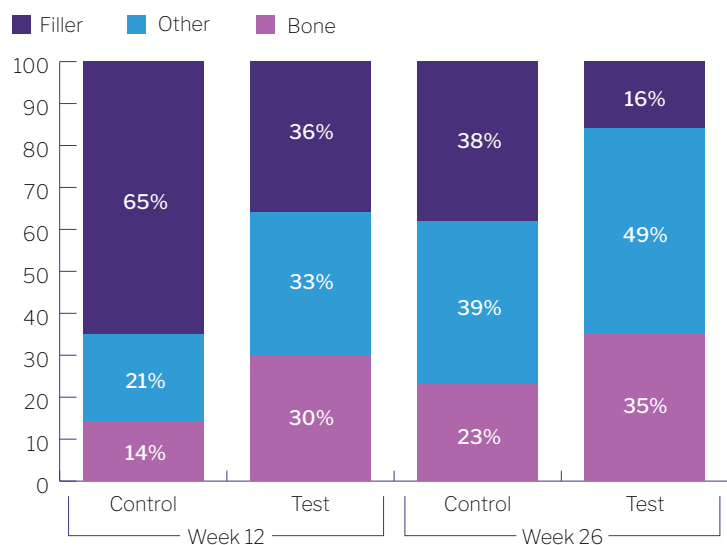


Figure 1: Mean percent tissue or filler within original drill defects of distal rabbit femurs healed at 12 or 28 weeks and filled originally with either Control or Test materials

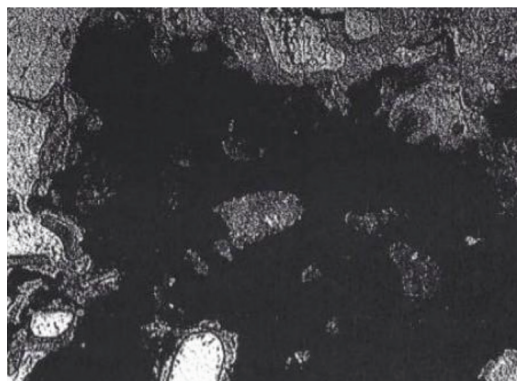


Figure 3: Test femur, animal No. 49452L, test bone void filler. Minimal osseous integration with no evidence of fibrous encapsulation or inflammation, Toluidine Blue stain, 20X.

Histomorphometric Study (NAMS 06T-26537-06)

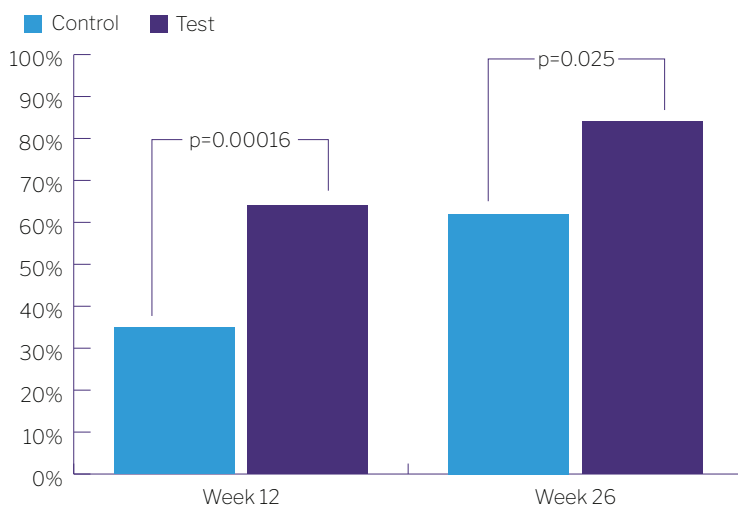


Figure 2: Mean percent fill resorption within original drill defects of distal rabbit femurs healed at 12 or 26 weeks and filled originally with either Control or Test materials.

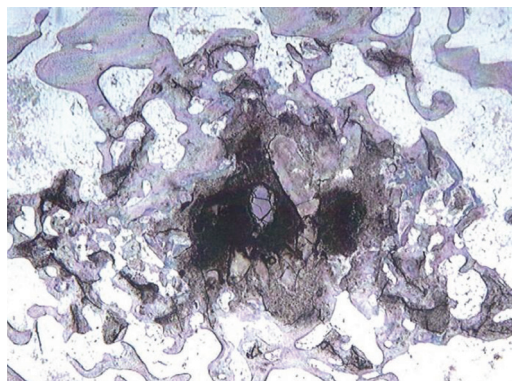


Figure 4: Test femur, animal No. 49456R, test bone void filler. Moderate osseous integration with no evidence of fibrous encapsulation or inflammation. Toluidine Blue stain, 20X.



MG-WP2 RevA

For the IFU on this product, please visit:
www.paragon28.com/ifus

Mgnum™ BVF is manufactured by Bones Solutions Inc. and distributed strictly by Paragon 28® in Foot and Ankle Orthopedic markets

Paragon 28, Inc
14445 Grasslands Dr.
Englewood, CO 80112 USA
(855) 786-2828

For the contraindications, potential complications and adverse reactions, warnings and precautions associated with this device, please refer to the device specific instructions for use at <http://www.paragon28.com/ifus>