

PRESERVE™

B O N E G R A F T

S Y S T E M

TECHNICAL MONOGRAPH

SUMMARY

The PRESERVE™ Bone Graft System

Safe and Efficacious

- ▶ 13,000+ grafts distributed¹
- ▶ 8+ year history of use
- ▶ <0.15% complaint rate²



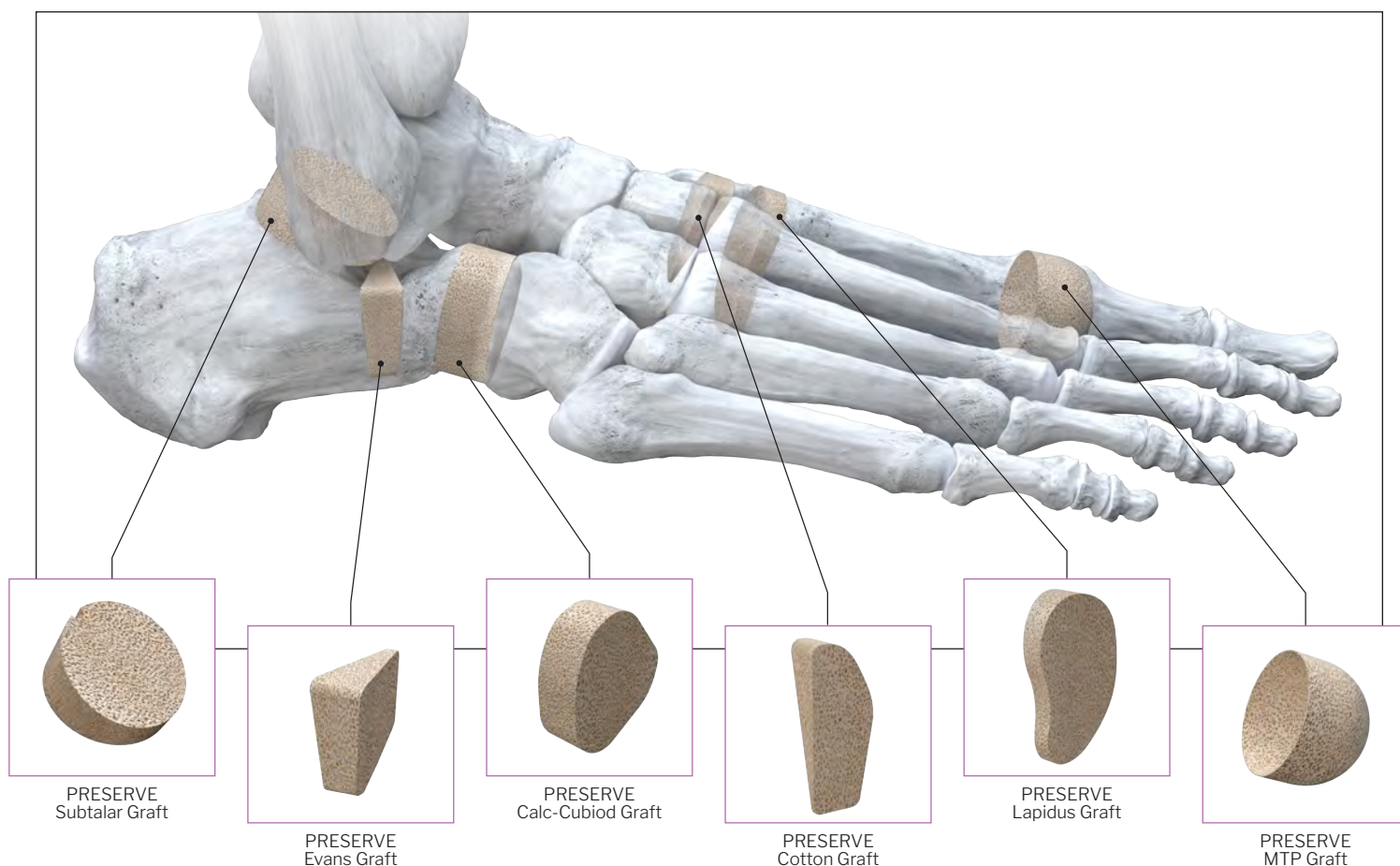
Compare to:

- ▶ Up to **20%** non-union for autograft³
- ▶ Up to **30%** complication rate for autograft⁴
- ▶ Up to **24%** non-union for structural allograft⁵

- ▶ **Eliminates the risks** associated with iliac crest graft harvesting
- ▶ Chronic pain, fracture and infection⁶

Unique, Patented Allografts

- ▶ Customized Aseptic Process
 - No gamma irradiation, No hydrogen peroxide, No bleach
- ▶ Patented procedure-specific shapes
- ▶ Made of dense cancellous bone
 - No cortical rim—faster incorporation, better union rate^{5,7}



RATIONALE AND SAFETY

Design Rationale

Paragon 28® launched the PRESERVE Bone Graft System to meet an unmet need of foot and ankle surgeons: to provide pre-shaped, anatomically specific, aseptically processed bone grafts. Since then, over 13,000 PRESERVE allografts have been implanted by hundreds of surgeons across the United States and in Europe. This innovative bone graft system was the first of its kind in foot and ankle and has gone on to reshape how surgeons think about allografts.

“The challenge is to prepare allografts that are well cleaned, sterile, and free of virus, while still preserving the natural biologic and biomechanical properties of the tissue.”

— Boyce, et al.⁸

Safety and Usage

The PRESERVE Bone Graft System has a complaint rate of less than 0.15% with an 8+ year history of safe use.²

PRESERVE Complaint Rate ² approx.	1 in 685
Iliac Crest Autograft Complication Rate ³	up to 3 in 10
Iliac Crest Autograft Non-Union Rate ⁴	up to 1 in 5
Structural Allograft Non-Union Rate ⁵	up to 1 in 4

PROVEN TRACK RECORD¹

Implanted by
900+ surgeons



Available in
850+ facilities



Sold across
all 50 States and Internationally

CLINICAL CASE STUDIES

Neglected Calcaneal Fracture

Dr. Thomas Chang, DPM — Clinical Professor, Department of Podiatric Surgery, California College of Podiatric Medicine

Presentation

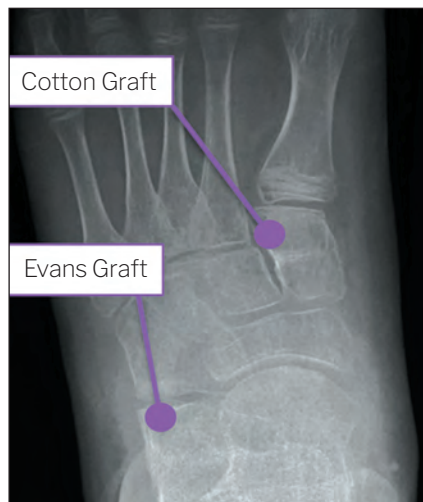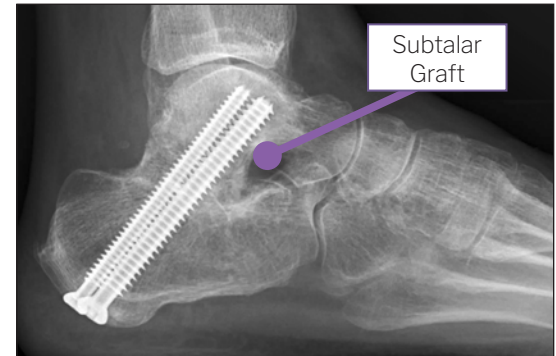
65 year-old female with daily hindfoot and ankle pain from neglected calcaneal fracture.

Corrective Procedure

Bone block distraction arthrodesis with **Subtalar PRESERVE Graft**

Outcome

At final follow-up (one year), radiograph shows improvement in talar declination angle and improved ankle joint alignment. Patient is able to perform daily activities with minimal pain and limitations.



PEDIATRIC FLATFOOT

Dr. Thomas Chang, DPM — Clinical Professor, Department of Podiatric Surgery, California College of Podiatric Medicine

Presentation

12 year-old male with arch pain and flatfoot collapse.

Corrective Procedure

- ▶ Evans osteotomy with **Evans PRESERVE Graft**
- ▶ Cotton osteotomy with **Cotton PRESERVE Graft**
- ▶ Gastrocnemius lengthening

Outcome

At one year post-operative, the radiograph shows excellent consolidation of the Evans and Cotton PRESERVE Grafts.

LAPIDUS ARTHRODESIS

Dr. Thomas San Giovanni, MD

- ▶ Clinical Professor, Florida International University, Herbert Wertheim College of Medicine
- ▶ Team Physician: Miami Dolphins, Florida Panthers, Miami FC

Presentation

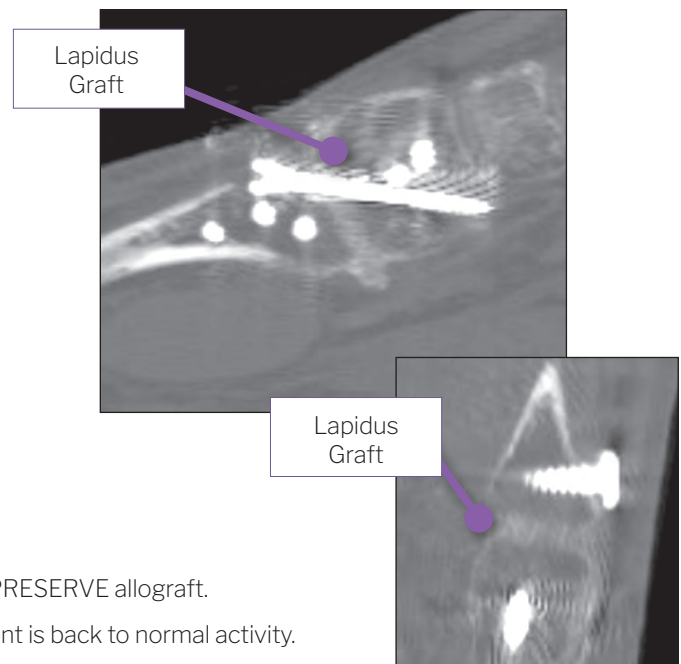
23 year-old female with hallux valgus and 1st TMT instability.

Corrective Procedure

- ▶ Lapidus arthrodesis with Lapidus PRESERVE Graft
- ▶ Derotation of 1st metatarsal
- ▶ Distal soft tissue realignment (modified McBride)

Outcome

- ▶ At 10 weeks, CT scan shows patient bone incorporation into the PRESERVE allograft.
- ▶ At one year post-operative, correction is maintained and the patient is back to normal activity.



BIOMECHANICAL TESTING

Comparison of the Biomechanical Properties of Non-Gamma Irradiated and Gamma Irradiated Dense Cancellous Bone⁹

Study Goal: To compare failure rates of dense cancellous bone under dynamic testing that have been processed with and without gamma irradiation. The hypothesis is that samples that have not been subjected to gamma irradiation will outperform samples that have been gamma irradiated in dynamic testing.

Methods: 72 cylindrical, freeze dried cancellous bone samples were tested under cyclic dynamic loading using a load cell. All samples were processed and tested at Community Tissue Services (Kettering, OH). Samples were processed using one of two methodologies:

Non-Gamma Processing


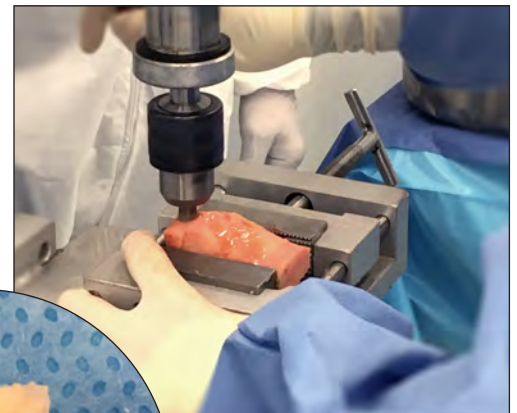
- ▶ Processed according to the protocol set for **PRESERVE Bone Grafts**

Gamma Processing

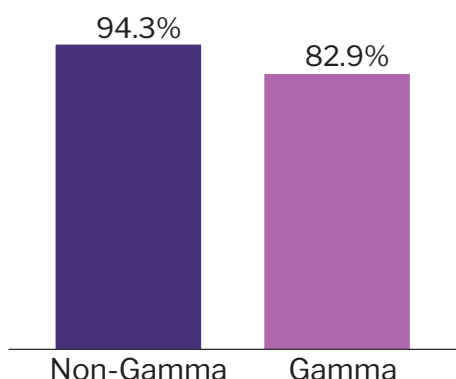
- ▶ Series of static soaks
- ▶ **Gamma irradiation at 13 kGy**

Dynamic Testing

- ▶ Ramp displacement at 1 N/s up to 7N compression
- ▶ Sinusoidal load waveform
- ▶ 27N amplitude (7N to 61N) at 2Hz
- ▶ 10,000 cycle runout



Dynamic Testing Success Rate



Results: Two samples (one aseptic and one gamma irradiated) were lost to testing equipment error, leaving 35 samples in each group. **Six gamma irradiated samples failed (17.1%)** compared to just **two from the radiation-free group (5.7%)**. Three of the gamma irradiated samples failed prior to reaching 4,000 cycles with one sample failing at 690 cycles.

Conclusion: Gamma irradiated bone samples failed at a higher rate than non-irradiated bone samples.

DENSE CANCELLOUS ALLOGRAFT

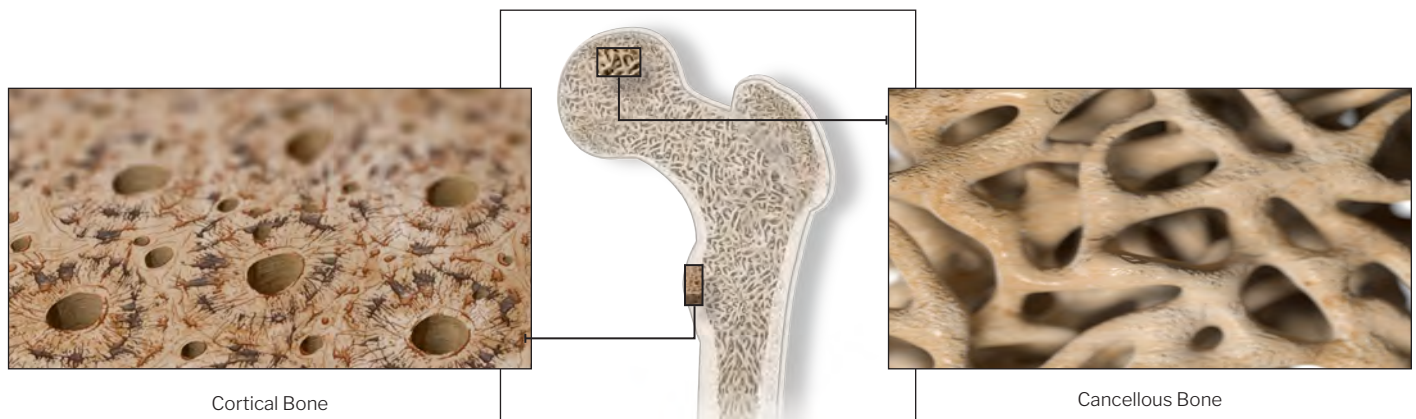
Why dense cancellous bone?

Faster Incorporation

- ▶ Cancellous bone is 8x more metabolically active than cortical bone.⁷
- ▶ Trabecular nature of cancellous bone has more surface area than cortical bone.⁷
 - More space for host osteoblasts and mesenchymal stem cells to incorporate.
- ▶ The osteointegration of cancellous graft is faster than cortical graft.⁷
 - Cortical bone walls must first be resorbed by osteoclasts.⁷
- ▶ More rapid revascularization for cancellous bone compared to cortical bone.
 - 2 days vs. 2 months⁷

Higher Union Rate

- ▶ 93.6% for cancellous allograft versus 86.9% for cortical allograft.⁵



Are dense cancellous allografts strong enough?

Paragon 28® works with experienced AATB accredited tissue banks to establish strict donor parameters, locations and guidelines to follow in order to get the **highest quality cancellous bone available**.

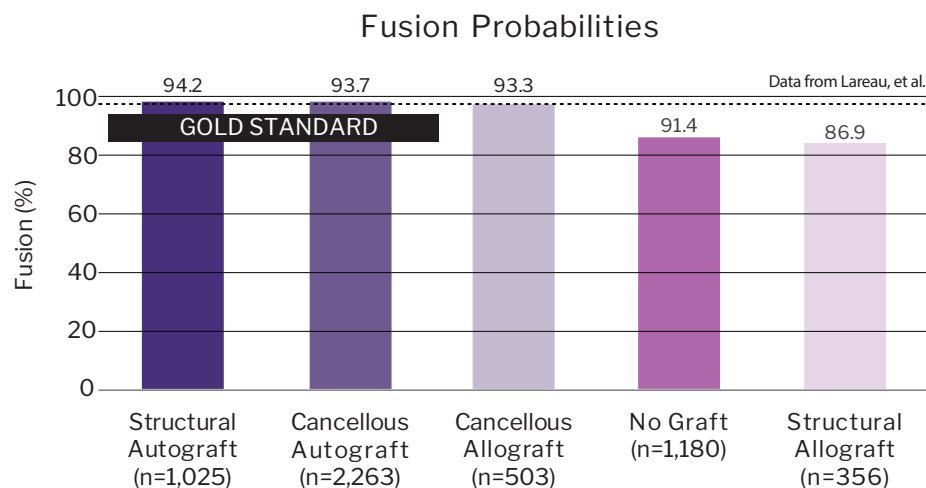
- ▶ **Select Donors**
 - Strict density requirements
- ▶ **High Density Donor Sites**
 - Femoral head, femoral calcar, distal femur, talus, patella, calcaneus and proximal tibia
 - Each graft must pass density requirements
- ▶ **Balanced Needs**
 - Structural demands are balanced with revascularization needs for every type of PRESERVE graft.
- ▶ **Customized Aseptic Processing**
 - Helps preserve the biomechanical properties of the bone.¹⁰

Although dense cancellous bone is not as inherently strong as cortical bone, allograft bone must be resorbed for osteointegration to occur. During this process, **cortical grafts may temporarily lose up to 75% of its mechanical strength.**^{7,11}

CLINICAL OUTCOMES OF ALLOGRAFT & AUTOGRAFT

Cancellous allograft, the category which PRESERVE bone grafts belong to, has demonstrated comparable fusion rates to the gold standard of autograft.

An independent study conducted by researchers at Harvard, Brown, Vanderbilt and OrthoCarolina found the fusion rate for cancellous allograft was effectively equal to that of the “gold standard”, cancellous autograft (93.3% vs 93.7%), and higher than structural allograft or those who did not receive a graft of any type.⁵



Foster reviewed 26 subjects who received a tricortical allograft that was fashioned intraoperatively from an iliac crest bone block.¹² They found 15.4% non-union, 30.8% hardware removal and 3.8% infection rate. The median time to union was 12 weeks.

Vosseller reviewed records from 126 lateral column lengthening (LCL) procedures from five surgeons.¹³ In total, 13.7% of the autograft group and 17.3% of the tricortical iliac crest allograft group failed.

Data from Vosseller, et al.

	Tricortical Iliac Crest Autograft	Tricortical Iliac Crest Allograft
# of Procedures	51	75
Non-Union	4 (7.8%)	9 (12.0%)
Loss of Correction	3 (5.9%)	4 (5.3%)
Failures	7 (13.7%)	13 (17.3%)

Muller found a non-union rate of 20% for subjects who underwent an LCL procedure with an iliac crest autograft.³

Luk reported a 13.3% non-union rate using hand-reamed tricortical iliac crest allograft in revision first MTP arthrodesis procedures.¹⁴

CUSTOMIZED ASEPTIC PROCESSING

“Irradiation is not a substitute for careful donor screening and viral assays.”

— Ng¹⁵

What is aseptic processing?

Aseptic processing requires that sterile tissue handling is employed in a controlled environment throughout all stages of processing.⁸ The fundamental methods to achieve this include: the utilization of sterile handling techniques during donor bone recovery, thorough graft debridement and cleansing, and the use of treatment solutions such as surfactants, alcohol and antibiotic solutions during cleaning while maintaining strict environmental and quality controls.⁸

How does aseptic processing differ from terminal sterilization?

In many situations, **some controls during processing using terminal sterilization are reduced**, and a sterilization technique (such as gamma irradiation) is employed to achieve sterility.⁸

Why wouldn't a surgeon want a terminally sterilized graft?

Terminal sterilization may alter biologic and biomechanical features of the graft and cause them to perform differently.^{8,10,16-20} This may lead to graft failure or non-union of the graft and subsequent revision surgeries.⁸

Paragon 28®'s customized aseptic processing technique narrows the donor pool to only the highest quality bone in terms of safety and performance.

PROCESSING EFFECTS ON BIOMECHANICAL PROPERTIES

“Processing techniques also can have a undesirable effect on graft strength, stiffness and the amount of energy absorbed.” — Boyce, et al.⁸

Gamma Irradiation:

- ▶ **Makes bone more brittle¹⁰**
- ▶ **Reduces functional life of bone¹⁰**
- ▶ **Reduces fatigue crack propagation resistance¹⁶**

Not all tissue processing methods are equal

Some tissue processes have been proven to compromise the biomechanical and biological properties of the allograft. **Thus, seemingly similar grafts may perform differently as a result of the processing procedures.⁸**

Currey studied the effects of radiation on human bone and concluded that even at relatively low doses, **radiation makes bone more brittle and reduces its energy-absorbing capacity.²¹**

Akkus compared gamma irradiated bone samples to non-irradiated bone samples from three young male donors (≤38 years old).¹⁰ **They found that irradiated bone samples had reduced biomechanical properties.**

↓ Yield strain (9.9% less)	↓ Post-yield energy (70.0%)
↓ Max stress (10.2% less)	↓ Energy to fracture (86.4% less)
↓ Fracture strain (60.5% less)	↓ Low-cycle fatigue (99.5% less)
↓ Elastic energy (14.3% less)	↓ High-cycle fatigue (99.0% less, estimated)

Gamma irradiation has also been shown to **reduce fatigue crack propagation resistance, shear strength, bending strength and compression strength** in cortical bone compared to non-irradiated bone.^{16,22}

Dux compared gamma irradiated bovine dense cancellous bone to controls and found that **irradiated samples had significantly more microfractures and an increase in residual strain.²³**

PROCESSING EFFECTS ON BIOLOGIC PROPERTIES

Hydrogen Peroxide

- ▶ Negatively impacts osteoinductivity of bone^{17, 24, 25}

Gamma Irradiation

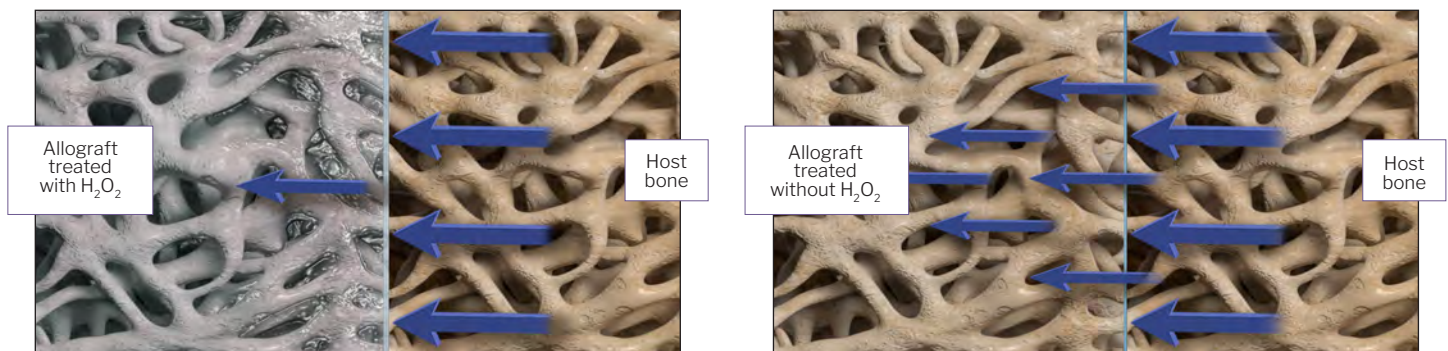- ▶ Inhibits osteoinductivity¹⁷⁻¹⁹
- ▶ Delays graft incorporation²⁰

In 2005, DePaula found that osteoinductivity decreased as hydrogen peroxide soak time increased.²⁴

Russell determined that hydrogen peroxide and gamma irradiation harm the osteoinductive properties of bone.¹⁷

Carpenter similarly concluded that hydrogen peroxide can damage osteoinductive capacity.²⁵

Osteoinductivity with and without hydrogen peroxide (H₂O₂)



Arjmand studied the effect of gamma irradiation on the osteoinductivity of bone and compared it to aseptically processed samples.¹⁸ Histopathology showed that new bone formation, chondrocytes, osteoblasts and angiogenesis all favored the aseptic allograft.

Han concluded that gamma irradiated demineralized bone matrix *“loses a significant degree of osteoinductivity”* when compared to non-irradiated samples.¹⁹ At 25kGy, all bone formation activity was virtually lost.

Voggenreiter used an animal model to investigate the incorporation of extracorporeal irradiated autogeneic cortical bone compared to controls and found:²⁰

- ▶ At 25 kGy, graft incorporation was delayed at 6, 9 and 12 weeks
- ▶ At 9 and 12 weeks, all irradiated groups showed less cortical bone formation, worse revitalization of the grafts and delayed incorporation
- ▶ Fracture was seen in 71.4% of the grafts irradiated at 50 kGy

In a comprehensive literature review, Nguyen stated that:²⁶

- ▶ The activity of osteoclasts is reduced when they are cultured onto irradiated bone slices
- ▶ Peroxidation of marrow fat increases apoptosis of osteoblasts
- ▶ Bacterial products remain after irradiation and induce inflammatory bone resorption following macrophage activation

REASONS FOR ALLOGRAFT BONE

There are many reasons why iliac crest harvesting should be avoided.²⁷

- ▶ Previous operations at or near the potential harvest area
- ▶ Systemic bony or neurological diseases
- ▶ Long standing treatments with steroids
- ▶ Immunosuppressive drugs
- ▶ Chemotherapy in the previous two months
- ▶ Drug misuse in the previous three months

Other factors that may elevate surgical risk or impact bone quality that should be taken into consideration prior to introducing a second surgical site to harvesting an autograft.

- ▶ Age²⁸
- ▶ Gender²⁸
- ▶ Tobacco use^{29,30}
- ▶ Diabetes^{31,32}

Surgical Site Infection

Increasing risk of surgical site infection is associated with increasing operative time.³³

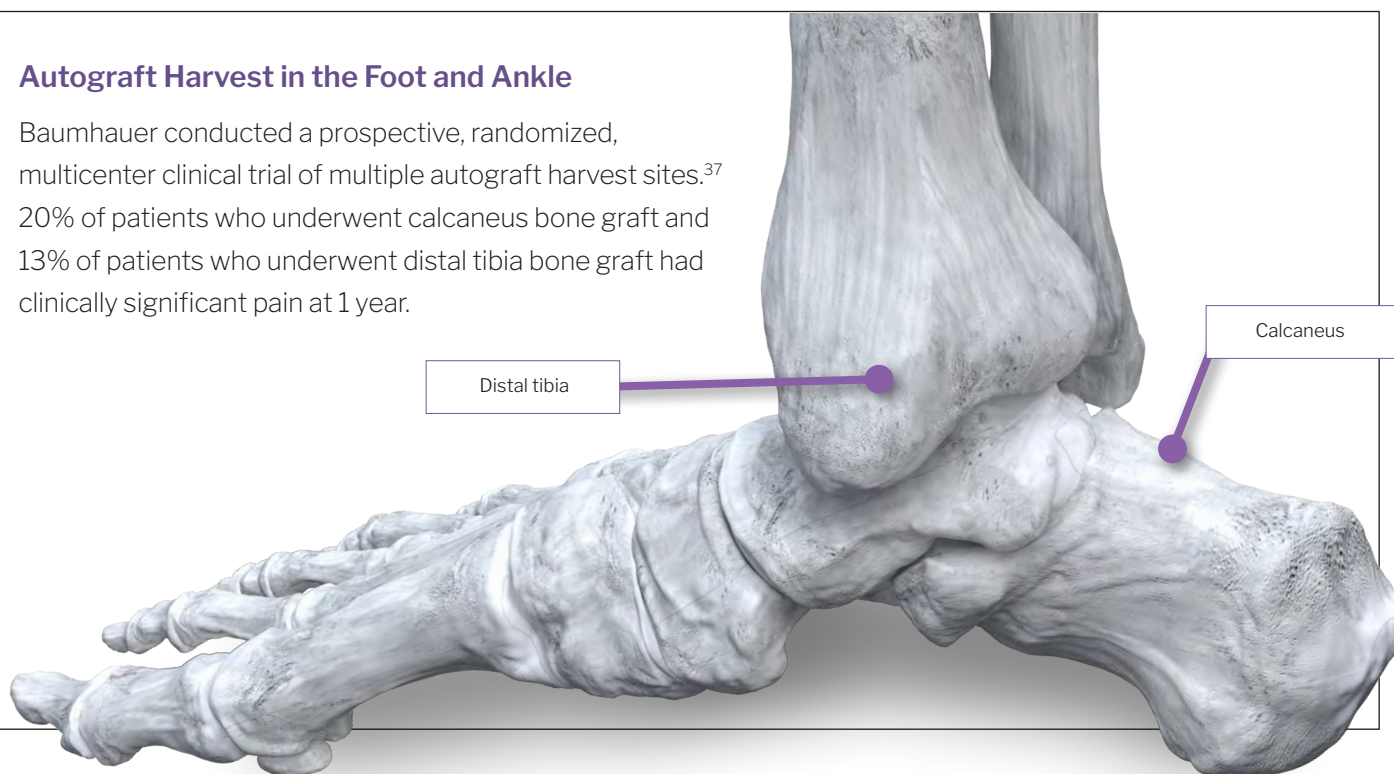
Several factors linked to prolonged surgical time may further increase the risk of infection.^{34,35}

“Currently, there are also commercially available sizers and preconfigured allografts (Paragon 28®). I prefer these systems in these bone block fusion scenarios, as they save operating room time and are less challenging to work with.”

— Schuberth and Hamilton³⁶

Autograft Harvest in the Foot and Ankle

Baumhauer conducted a prospective, randomized, multicenter clinical trial of multiple autograft harvest sites.³⁷ 20% of patients who underwent calcaneus bone graft and 13% of patients who underwent distal tibia bone graft had clinically significant pain at 1 year.



ILIAC CREST BONE HARVESTING: PAIN AND MORBIDITY

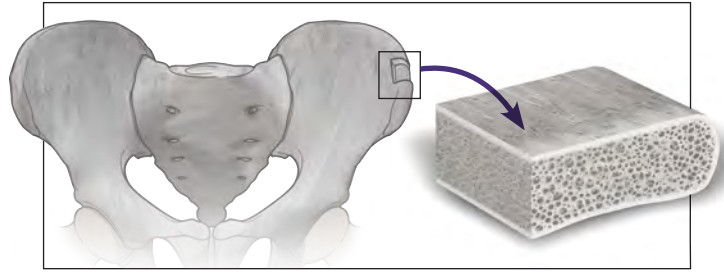
Complications Associated with Iliac Crest Bone Harvesting:

- ▶ Pain^{6,38,39}
- ▶ Fracture^{4,6,38}
- ▶ Infection⁶
- ▶ Hematoma⁶
- ▶ Seroma⁶
- ▶ Nerve injury^{6,38,40,41}
- ▶ Arterial injury^{6,38}
- ▶ Peritoneal perforation³⁸
- ▶ Sacroiliac joint instability³⁸
- ▶ Herniation of abdominal contents through defects in the ilium³⁸
- ▶ Wound Dehiscence⁶
- ▶ Scarring^{6,41}

Kim published findings from a prospective study looking at iliac crest bone graft harvest site pain and morbidity.⁴¹

At 1 year post-op:

- ▶ 16.5% had more severe pain from harvest site than from primary surgical site
- ▶ 29.1% had noticeable numbness
- ▶ 11.3% had bothersome numbness
- ▶ 3.9% were bothered by scar appearance



A systematic literature review of 6,449 patients to assess complications after bone graft harvesting from the iliac crest showed that 19.4% of patients experienced donor site complications, including 91 cases of infection. 7.8% of the patients had chronic pain at the harvest site.⁶

Huang reported a 30% complication rate at the harvest site for subject undergoing an anterior iliac crest autograft procedure including harvest site fracture.⁴

Injury to the lateral femoral cutaneous nerve can occur in up to 20% of patients during iliac crest bone harvesting.⁴⁰







Patients also experienced functional disability due to persistent harvest site pain.

- ▶ 15.1% difficulty walking
- ▶ 5.2% difficulty with their job
- ▶ 12.9% difficulty with recreational activities,
- ▶ 14.1% difficulty with household chores
- ▶ 7.6% difficulty with sexual activity
- ▶ 5.9% irritation from clothing

Bone Harvesting in Pediatric Patients

Bone grafts are commonly used in pediatric patients who require corrective skeletal surgery. It has been stated that pediatric autograft can sometimes lead to “disastrous consequences”.⁴² In addition to the typical complications associated with iliac crest bone harvesting, children and adolescents may also experience disturbance in the growth of the iliac wing.⁴³ Kager et al. reported that 10% of adolescents had harvest site pain at 1 year after undergoing an iliac crest autograft procedure.³⁹

DENSE CANCELLOUS ALLOGRAFTS

Graft		Size Offering	Primary Donor Site	Features
Evans		6 mm 8 mm 10 mm 12 mm	<ul style="list-style-type: none"> • Patella • Talus • Femoral Calcar 	<ul style="list-style-type: none"> • Patented dorsal to plantar taper and lateral to medial taper allows for multi-plane correction while avoiding higher stresses to the long plantar ligament. • Rounded corners dorsally and plantarly help prevent soft tissue irritation. • Donor bone is cut to allow for the dorsolateral corner to have the highest density—allows the surgeon to tamp on the bone graft in this area to facilitate insertion.
Cotton		5 mm 6 mm 7 mm 8 mm	<ul style="list-style-type: none"> • Patella • Talus • Femoral Calcar 	<ul style="list-style-type: none"> • Patented shape has a rounded dorsomedial corner to match the curvature of the medial cuneiform. • Donor bone is cut to allow for the dorsal portion of the graft to have the highest density—allows the surgeon to tamp on the bone graft in this area to facilitate insertion.
Lapidus		5 mm x 5° 8 mm x 8° 10 mm x 10° 12 mm x 12° 14 mm Universal (Parallel)	<ul style="list-style-type: none"> • Distal Femur 	<ul style="list-style-type: none"> • Patented kidney bean shape provides biplanar correction from dorsal to plantar and medial to lateral along an axis to provide plantarflexion and abduction of the 1st metatarsal. • Donor bone is cut to allow for the dorsomedial portion of the graft to have the highest density—allows the surgeon to tamp on the bone graft in this area to facilitate insertion.
MTP		19 x 5 mm 19 x 8 mm 19 x 10 mm 19 x 15 mm 19 x 20 mm 21 x 5 mm 21 x 8 mm 21 x 10 mm	<ul style="list-style-type: none"> • Distal Femur 	<ul style="list-style-type: none"> • Patented convex/concave design allows the hallux position to be adjusted in all 3 planes, without having to re-cut to adjust planar correction. • Convex and concave shapes maximize surface area interaction between recipient bone and graft.
Subtalar		10 mm 12 mm 14 mm 16 mm 18 mm Universal (Parallel)	<ul style="list-style-type: none"> • Distal Femur • Talus • Patella • Femoral Calcar 	<ul style="list-style-type: none"> • 10 mm–16 mm grafts add height and varus/valgus correction. • Angle of correction is proportional to the height of the graft. • The round shape allows the wedge to be rotated to the desired correction to accommodate a wide range of anatomical shapes.
Calcaneo-Cuboid		8 mm 10 mm 12 mm 14 mm 16 mm 18 mm Universal (Parallel)	<ul style="list-style-type: none"> • Distal Femur • Talus • Calcaneus • Femoral Calcar 	<ul style="list-style-type: none"> • Tapered from medial to lateral to allow for ease of insertion. • As width of wedge increases medial to lateral taper of wedge proportionally increases.

PROCEDURE SPECIFIC INSTRUMENTATION

Evans & Cotton Allograft Trial Caddy



Cotton Trials

Evans Trials

Trial handles, K-wires and a bone tamp are included in the PRESERVE Evans & Cotton Allograft Trial Caddy.

Lapidus Allograft Trial Caddy



Lapidus Trials

Trial handles, K-wires, and a curved bone tamp are included in the PRESERVE Lapidus Allograft Trial Caddy.


MTP Allograft Trial Caddy



MTP Trials

Trial handles, K-wires and patented spin guard reamers (Patent # 10,064,631) are included in the PRESERVE MTP Allograft Trial Caddy.

Subtalar & Calc-Cuboid Allograft Trial Caddy



Subtalar Trials

Calc-Cuboid Trials

Trial handles, K-wires and a curved bone tamp are included in the PRESERVE Subtalar & Calc-Cuboid Allograft Trial Caddy.

REFERENCES

1. Internal data as of November 2018.
2. Internal complaint records as of November 2018.
3. Muller SA, et al. Autograft versus sterilized allograft for lateral calcaneal lengthening osteotomies: Comparison of 50 patients. *Medicine (Baltimore)*. 2016;95(30):e4343.
4. Huang Y-C, et al. Comparing morbidities of bone graft harvesting from the anterior iliac crest and proximal tibia: a retrospective study. *J Orthop Surg Res*. 2018;13(1):115.
5. Lareau CR, et al. Does autogenous bone graft work? A logistic regression analysis of data from 159 papers in the foot and ankle literature. *Foot Ankle Surg*. 2015;21(3):150-159.
6. Dimitriou R, et al. Complications following autologous bone graft harvesting from the iliac crest and using the RIA: a systematic review. *Injury*. 2011;42 Suppl 2:S3-S15.
7. Pape HC, et al. Autologous bone graft: properties and techniques. *J Orthop Trauma*. 2010;24 Suppl 1:S36-40.
8. Boyce T, et al. Allograft bone. The influence of processing on safety and performance. *Orthop Clin North Am*. 1999;30(4):571-581.
9. Wisbeck J, et al. Comparison of the Biomechanical Properties of Non-Gamma Irradiated and Gamma Irradiated Dense Cancellous Bone. In: Las Vegas, NV: ACFAS Scientific Conference; 2017.
10. Akkus O, et al. Sterilization by gamma radiation impairs the tensile fatigue life of cortical bone by two orders of magnitude. *J Orthop Res*. 2005;23(5):1054-1058.
11. Goldberg VM, et al. Biological and physical properties of autogenous vascularized fibular grafts in dogs. *J Bone Joint Surg Am*. 1990;72(6):801-810.
12. Foster JR, et al. Union Rates and Complications of Lateral Column Lengthening Using the Interposition Plating Technique: A Radiographic and Medical Record Review. *J Foot Ankle Surg*. 2017;56(2):247-251.
13. Vosseller JT, et al. Autograft and allograft unite similarly in lateral column lengthening for adult acquired flatfoot deformity. *HSS J*. 2013;9(1):6-11.
14. Luk PC, et al. First Metatarsophalangeal Joint Arthrodesis Technique With Interposition Allograft Bone Block. *Foot ankle Int*. 2015;36(8):936-943.
15. Ng VY. Risk of disease transmission with bone allograft. *Orthopedics*. 2012;35(8):679-681.
16. Mitchell EJ, et al. The effect of gamma radiation sterilization on the fatigue crack propagation resistance of human cortical bone. *J Bone Joint Surg Am*. 2004;86-A(12):2648-2657.
17. Russell N, et al. The Effect of Processing Conditions of the Osteoinductivity of Sheep Demineralized Bone Matrix in an Ectopic Nude Rat Model: A Pilot Study. In: ORS; 2012:Poster 0629.
18. Arjmand B, et al. The effect of gamma irradiation on the osteoinductivity of demineralized human bone allograft. *Acta Med Iran*. 2014;52(3):215-219.
19. Han B, et al. Effects of gamma irradiation on osteoinduction associated with demineralized bone matrix. *J Orthop Res*. 2008;26(1):75-82.
20. Voggenreiter G, et al. Extracorporeal irradiation and incorporation of bone grafts. Autogeneic cortical grafts studied in rats. *Acta Orthop Scand*. 1996;67(6):583-588.
21. Currey JD, et al. Effects of ionizing radiation on the mechanical properties of human bone. *J Orthop Res*. 1997;15(1):111-117.
22. Zhou Z, et al. Mechanical strength of cortical allografts with gamma radiation versus ethylene oxide sterilization. *Acta Orthop Belg*. 2011;77(5):670-675.
23. Dux SJ, et al. Alterations in damage processes in dense cancellous bone following gamma-radiation sterilization. *J Biomech*. 2010;43(8):1509-1513.
24. DePaula CA, et al. Effects of hydrogen peroxide cleaning procedures on bone graft osteoinductivity and mechanical properties. *Cell Tissue Bank*. 2005;6(4):287-298.
25. Carpenter EM, et al. Effect of hydrogen peroxide on osteoinduction by demineralized bone. *Am J Orthop (Belle Mead NJ)*. 2006;35(12):562-567.
26. Nguyen H, et al. Sterilization of allograft bone: effects of gamma irradiation on allograft biology and biomechanics. *Cell Tissue Bank*. 2007;8(2):93-105.
27. Labianca L, Calderaro C, Montanaro A, et al. Tips and Tricks in Harvesting of Bone from the Iliac Crest. *American Academy of Orthopaedic Surgeons*. <https://www.aaos.org/CustomTemplates/VideoGallery.aspx?id=4294972203&nav=348&ssopc=1>. Accessed October 3, 2018.
28. Berntsen GK, et al. Forearm bone mineral density by age in 7,620 men and women: the Tromso study, a population-based study. *Am J Epidemiol*. 2001;153(5):465-473.
29. Law MR, et al. A meta-analysis of cigarette smoking, bone mineral density and risk of hip fracture: recognition of a major effect. *BMJ Br Med J*. 1997;315(7112):841-846.
30. Turan A, et al. Smoking and Perioperative Outcomes. *Anesthesiology*. 2011;114(4):837-846.
31. Myers TG, et al. Ankle and hindfoot fusions: comparison of outcomes in patients with and without diabetes. *Foot ankle Int*. 2012;33(1):20-28.
32. Martin ET, et al. Diabetes and Risk of Surgical Site Infection: A systematic review and meta-analysis. *Infect Control Hosp Epidemiol*. 2016;37(1):88-99.
33. Cheng H, et al. Prolonged Operative Duration Increases Risk of Surgical Site Infections: A Systematic Review. *Surg Infect (Larchmt)*. 2017;18(6):722-735.
34. An APIC Guide- Guide to the Elimination of Orthopedic Surgical Site Infections. 2010.
35. Lynch RJ, et al. Measurement of foot traffic in the operating room: implications for infection control. *Am J Med Qual*. 2009;24(1):45-52.
36. Schuberth JM, et al. End-Stage Osteoarthritis of the First Metatarsophalangeal Joint: What Has Changed in Our Practice? *Foot Ankle Spec*. 2018;11(4):357-361.
37. Baumhauer J, et al. Site selection and pain outcome after autologous bone graft harvest. *Foot ankle Int*. 2014;35(2):104-107.
38. Kurz LT, et al. Harvesting autogenous iliac bone grafts. A review of complications and techniques. *Spine (Phila Pa 1976)*. 1989;14(12):1324-1331.
39. Kager AN, et al. Morbidity of Iliac Crest Bone Graft Harvesting in Adolescent Deformity Surgery. *J Pediatr Orthop*. 2006;26(1).
40. Murata Y, et al. Injury to the lateral femoral cutaneous nerve during harvest of iliac bone graft, with reference to the size of the graft. *J Bone Joint Surg Br*. 2002;84(6):798-801.
41. Kim DH, et al. Prospective study of iliac crest bone graft harvest site pain and morbidity. *Spine J*. 2009;9(11):886-892.
42. Docquier P-L, et al. The use of allografts in paediatric orthopaedic surgery. *Acta Orthop Belg*. 2007;73(5):551-557.
43. Rossillon R, et al. Growth disturbance of the ilium after splitting the iliac apophysis and iliac crest bone harvesting in children: a retrospective study at the end of growth following unilateral Salter innominate osteotomy in 21 children. *Acta Orthop Belg*. 1999;65(3):295-301.

PRESERVE™

BONE GRAFT

SYSTEM

Patent Numbers

D691,272

D813,394

D720,456

9,452,057

D740,424

9,848,893

D720,457

Acknowledgment:


Paragon 28® would like to thank Dr. Thomas Chang, DPM and Dr. Thomas San Giovanni, MD for their contributions to the clinical case studies.

Paragon 28's PRESERVE™ Bone Graft System is a human cell, tissue, and cellular and tissue-based product (HCT/P) that is regulated under 21 CFR 1271.3(d)(1) and Section 361 of the Public Health Service Act and is intended for homologous use only.

P01-TM-0001 RevD

2023-02-10

Distributed by:

Paragon 28, Inc. 

14445 Grasslands Dr.

Englewood, CO 80112 USA

(855) 786-2828

Paragon 28 Medical Devices Trading Limited

+353 (0) 1588 0350

First Floor Block 7 Beckett Way

Park West Business Park

Dublin 12, D12 X884

Ireland

™Trademarks and ®Registered Marks of Paragon 28®, Inc. © Copyright 2023 Paragon 28®, Inc. All rights reserved. Patents: www.paragon28.com/patents

CE 2797

Exclusively foot & ankle
Paragon²⁸

www.Paragon28.com