



## CHARCOT NEUROPATHY AND ANKLE ARTHRITIS

### FEATURED PRODUCTS:

V92-FC+™ Cellular Bone Matrix

Monster® Hindfoot Screw

Joust™ Beaming Screws

Surgeon Author: Christopher Gross, MD  
Practice and Faculty: Medical University of South Carolina, Charleston, SC

## V92-FC+™ Product Introduction

V92-FC+™ is a viable allograft with an average of 1.5 million cells/cc of allograft packaged in a convenient syringe which thaws quickly and retains viability for four hours post thaw to accommodate clinical needs. The excellent handling characteristics of the allograft provide the surgeon with many opportunities of clinical placement, from packing and shaping to easy administration through a 6 mm bone funnel. The allograft provides the three key elements of bone formation. The foundation is an osteoconductive and osteoinductive bone scaffold composed of cancellous chips and demineralized cortical fibers to deliver a 100% human-derived product that mimics the structure of native bone. The third element in V92 FC+ are viable endogenous bone cells that support the osteogenic potential of this graft during the healing process. V92-FC+™ utilizes a novel cryoprotectant for preservation of the cell component that is DMSO-free so there is no need to rinse or decant during the preparation of the product.

## Charcot Arthropathy

Charcot arthropathy is a neurotraumatic and degenerative foot disorder commonly seen in patients with dense peripheral neuropathy, which can greatly affect quality of life in these patients. Although nonoperative management remains the primary treatment modality, surgical reconstruction, such as extended medial column arthrodesis with beams, can restore plantigrade foot anatomy with decreased soft tissue dissection and improved bone compression for arthrodesis. These patients challenge our ability to rely on traditional hardware constructs for fixation.

Beaming arthrodesis has also been shown to balance load distribution and reduce the incidence of deformity and ulceration in Charcot feet. There are only a few case series reported, however, proposed advantages include a decrease in soft tissue damage, reduction in the amount of implanted hardware, and improved bone compression.

### CASE 1: Mid and Hindfoot Fusion

The patient is a 68 year old female who presented to our clinic with continued midfoot pain following a 2nd tarsometatarsal (TMT) arthrodesis by a local surgeon. The patient presented one year following her index procedure given her increasing deformity and pain along her medial arch. She has a significant past medical history of diabetes relatively well controlled with an HbA1c of 6.7. Her examination was notable for a loss of protective and light touch sensation in all nerve distributions. She was in 15 degrees of hindfoot valgus and had a loss of arch height.

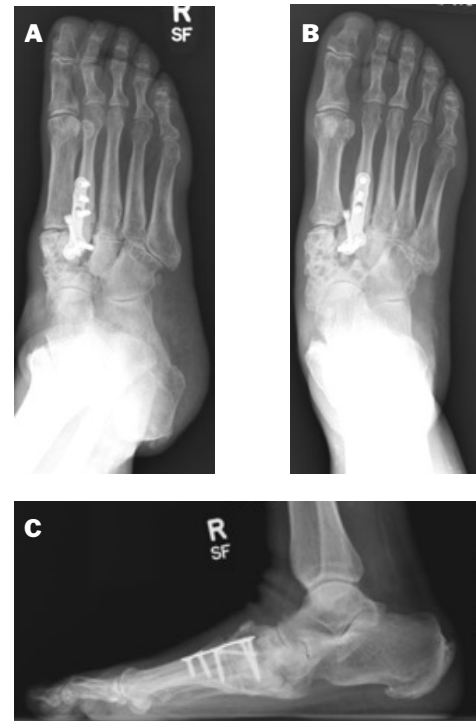

Figure 1 (A–C): AP/lateral/oblique views of 62-year-old female with continued pain and deformity following a 2nd TMT fusion

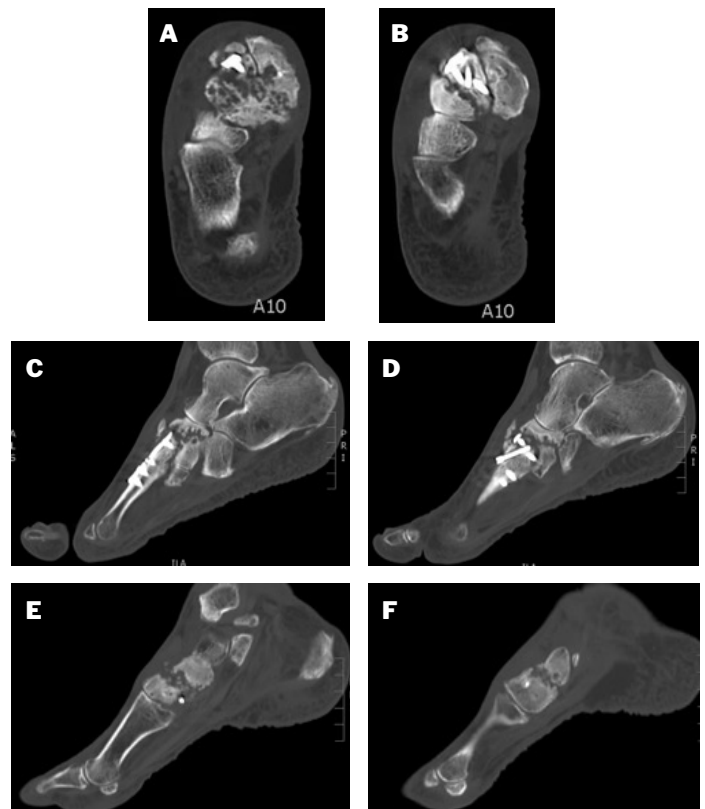


Figure 2 (A–F): 62-year-old female with continued midfoot pain. CT scans of nonunion and scattered degenerative findings throughout

## Radiographic Examination

Weightbearing x-rays and CT scan of the foot were obtained (Figures 1 and 2). A nonunion of the 2nd TMT joint was visualized. There was noted to be significant arthritic changes throughout her midfoot.

## Initial Management and Decision Making

Treatment options were discussed with the patient. We elected to perform a neuropathic beaming reconstruction given that she had failed a 2nd TMT arthrodesis and had scattered midfoot arthritis, hindfoot malignment and arch collapse, and was neuropathic.

## Surgical Technique

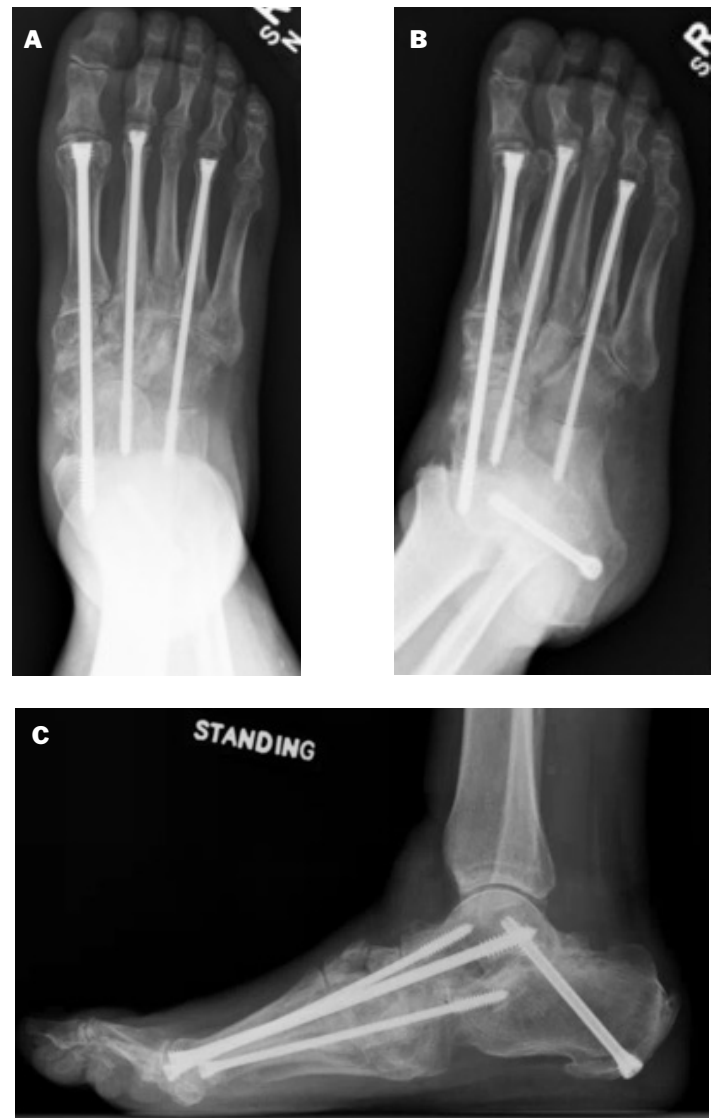When reconstructing a neuropathic deformity, we start proximally and go distally in order to correct the deformities to achieve a plantigrade foot. We first made an oblique incision over the sinus tarsi and dissected to the posterior facet. Using a half-inch curved osteotome, we removed the articular surfaces of the talus and calcaneus. We removed any remaining cartilage until the subchondral plate was exposed. We then used a Paragon 28 fenestration drill bit to further prepare the joint. Next, we packed the cavity with roughly 2.5cc of Paragon 28 V92-FC+™ Cellular Matrix and 7.5cc of crushed cancellous bone allograft chips. Next, we reduced the hindfoot into neutral alignment and placed a 7.0 Monster® Hindfoot Screw to compress the joint.

Next, we made a medial incision over the medial column. We used an osteotome and curettes to prepare the 1st TMT, navicular cuneiform joint, and talonavicular joint. Then we used the prior dorsal 2nd TMT incision and removed the hardware. We then re-prepared the joint. Next, we filled each joint with a combination of 7.5cc of V92-FC+™ Cellular Matrix and crushed cancellous bone allograft chips. We then made a separate incision over the calcaneocuboid joint and prepared the joint. We placed a small amount of V92-FC+™ and allograft chips in the joint.

We reduced the foot with several K-wires (decreasing Meary's angle in the AP and lateral view). Next, we used the Paragon Joust Beaming Screw System guidewires and placed them percutaneously through the 1st, 2nd, and 4th metatarsophalangeal joints. After incisions were made over the respective joints, we reamed and placed the 1st, 2nd, and 4th Joust™ Beams down the medial, middle, and lateral column (7.0mm, 5.5mm, and 5.5mm respectively). All wounds were irrigated thoroughly. Vancomycin was placed in the wounds and tranexamic acid was given intravenously to the patient. The wounds were closed in layers. The patient was then placed in a non-weightbearing splint.

## Post operative protocol

The patient was seen two weeks post-operatively wherein we removed sutures and placed her into a short leg nonweightbearing cast (SLNWBC) for the next four weeks. She was seen in a weightbearing CAM boot for four more weeks. At six months post-operatively (Figure 3) radiographs demonstrated maintained alignment and complete healing of her midfoot. She had no pain and no longer relied on inserts to walk. She was pleased with the results of her surgery and started the process of signing up for a midfoot reconstruction on the contralateral foot.



**Figure 3 (A–C):** Healed subtalar fusion and middle, medial, and lateral column fusion.

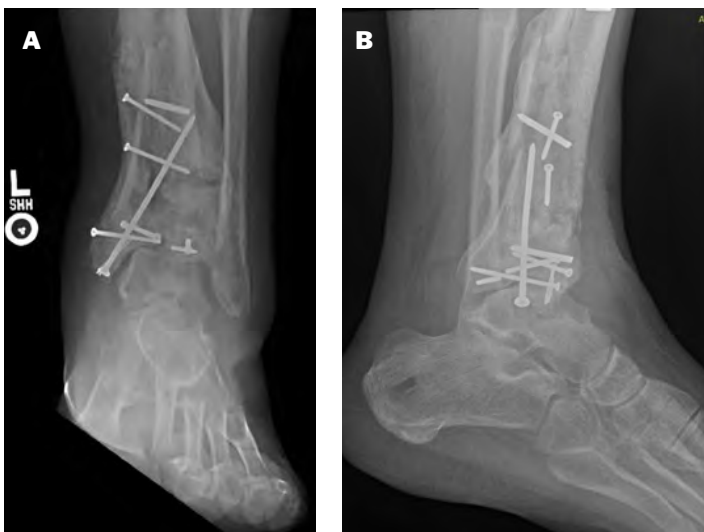
## CASE 2: Ankle Fusion

The second patient is a 35-year-old veteran with an extensive surgical history of his left ankle due to shrapnel from an improvised explosive device (IED) while serving in Iraq. He initially suffered from an open blast injury to his left ankle that resulted in a Type III open pilon fracture. He underwent a washout and external fixator placement in the field military hospital. He was then air transported to Germany wherein he had limited fixation of his pilon given the gross contamination of his wounds. He was left in the external fixator for three months. The patient was medically discharged from the Marines due to this injury. He had another surgery to remove some screws due to concerns for infection two years after his injury. He presented to the clinic five years later with complaints of constant swelling in his ankle and severe pain.

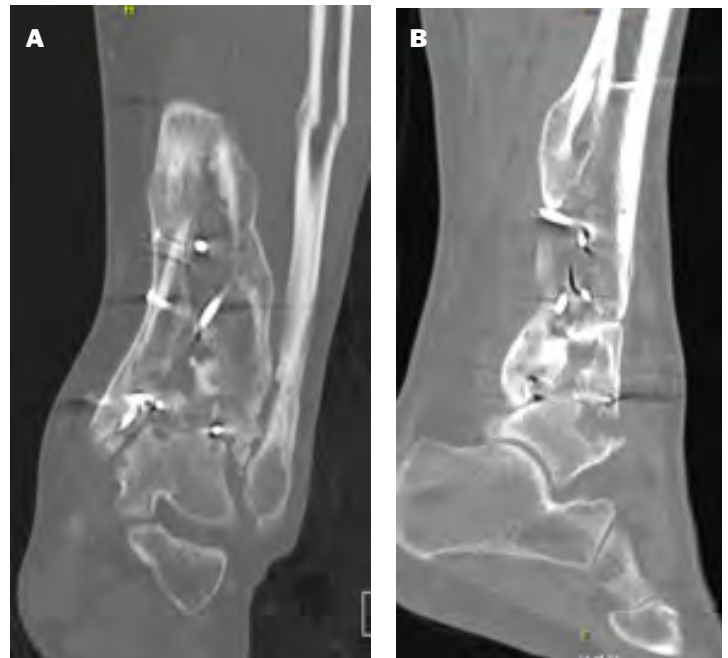The patient had a BMI of 36. On examination, he had minimal but painful motion of his ankle joint. There were areas of skin compromise laterally and medially. He had decreased sensation to light touch in all distributions. He did reveal he was a current smoker. We counseled the patient that surgery was contingent on cessation of smoking prior to surgery.

### Radiographic Examination

Weightbearing x-rays and CT scan of the ankle were obtained (Figure 4, A–B and Figure 5, A–B). Severe arthritis was noted at the ankle joint with sparing of the subtalar joint. There were many areas of osseous nonintegration and loss and the area included several broken screws.



**Figure 4 (A–B):** AP and lateral x-ray of the ankle demonstrating severe ankle arthritis and talus subluxation.



**Figure 5 (A–B):** CT scan views of ankle which demonstrates areas of bone void and severe arthritis.

### Initial Management and Decision Making

Given his swelling and broken hardware, we ordered inflammatory labs and a cotine level pre-operatively. It revealed no active or chronic inflammation. He had successfully stopped smoking. Given the patient's functional demands, obesity, and age we elected to perform a mini-open ankle fusion with screw fixation. Of note during our laboratory testing, he found that he had an HbA1c of 7.5.

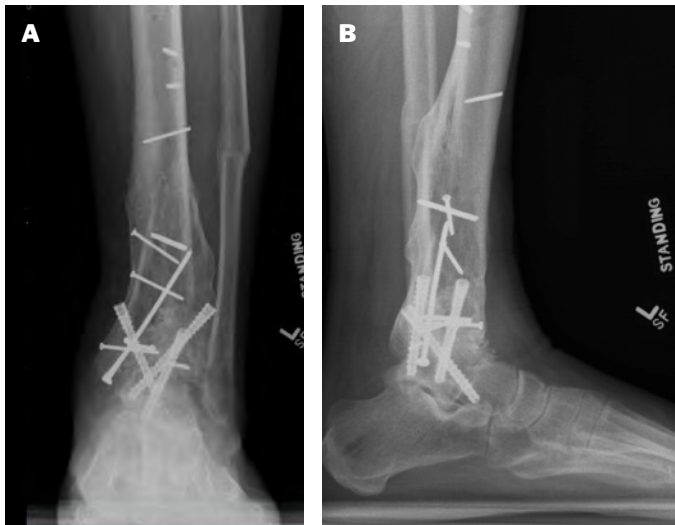
### Surgical Technique

First, we harvested bone marrow aspirate (BMA) from the ipsilateral iliac crest. We placed an incision 4 cm over the midline of the anterior ankle. The incision was centered over 1/2 of the tibia and 1/2 of the talus. After we incised the skin, we dissected down to the anterior retinacular layer, careful to avoid or identify and protect the superficial peroneal nerve. We made a small nick in the retinacular layer and then used Metzenbaum scissors to carefully release the exposed retinaculum. At this point, the tibialis anterior was exposed. We pulled the tendon medially and incised sharply down to tibia, careful to avoid the neurovascular bundle. We then incised into the capsule. The joint was

inspected and found to be severely arthritic. We prepared the joint with Paragon 28 curettes from the Silverback™ Ankle Fusion Plating set. Once we had prepared the joint and fenestrated it, we placed a mixture of 4 cc of BMA, 10 cc of V92-FC+™ Cellular Bone Matrix, and 15 cc of crushed cancellous allograft. We then placed three 7.0 cannulated screws across the fusion site—one medial, one lateral, and one posterior to anterior. Vancomycin was placed in the wound and tranexamic acid was given intravenously to the patient. The incision was closed in layers. The patient was then placed in a non-weightbearing splint.

## Post-operative Protocol

The patient was seen two weeks post-operatively wherein we removed sutures and placed him into a short leg nonweightbearing cast (SLNWBC) for the next four weeks. At that visit the patient revealed he had started smoking again. He was seen again at post-operative week 6 and his ankle x-rays demonstrated excellent alignment and incorporation of the graft material in his ankle joint. He was again placed into a cast and made nonweightbearing for six more weeks. At week 12, we again reimaged the ankle and saw complete healing across the ankle joint. HbA1c analysis revealed a value of 8.6 at this point. The patient was placed in a weightbearing CAM boot for four more weeks. At twelve months post-operatively (Figure 6, A–B) radiographs demonstrated maintained alignment and complete healing of his ankle. His swelling was reduced significantly, and his pain was much improved.



---

P01-CS-0004 Rev A [2024-04-17]

™Trademarks and ®Registered Marks of Paragon 28®, Inc.

© Copyright 2023 Paragon 28®, Inc. All rights reserved.

Patents: [www.paragon28.com/patents](http://www.paragon28.com/patents)

Paragon 28, Inc. 🏢

14445 Grasslands Dr.

Englewood, CO 80112 USA

(855) 786-2828



[www.Paragon28.com](http://www.Paragon28.com)