



V92-FC+™ CELLULAR BONE CASE SERIES

***FEATURED PRODUCTS: V92-FC+™ Cellular Bone Matrix,
Monster® Hindfoot Screw System, Gorilla® Calc Fracture Plating System,
Phantom® ActivCore Nail System, Gorilla® Universal Plating System***

Surgeon Author: Michael Gentile, DPM
Practice: Marshall University School of Medicine, Huntington, WV
Faculty: Marshall University School of Medicine, Huntington, WV

V92-FC+™ Product Introduction

V92-FC+™ is a viable allograft with an average of 1.5 million cells/cc of allograft packaged in a convenient syringe which thaws quickly and retains viability for four hours post thaw to accommodate clinical needs. The excellent handling characteristics of the allograft provide the surgeon with many opportunities for clinical placement, from packing and shaping to easy administration through a 6 mm bone funnel. The allograft provides the three key elements of bone formation. The foundation is an osteoconductive and osteoinductive bone scaffold composed of cancellous chips and demineralized cortical fibers to deliver a 100% human-derived product that mimics the structure of native bone. “The third element are the MIAMI cells (Marrow Isolated Adult Multi-Lineage Induced cell) packed into V92-FC+ that power osteogenesis.” V92-FC+™ utilizes a novel cryoprotectant for preservation of the cell component that is DMSO-free so there is no need to rinse or decant during the preparation of the product.

CASE 1: Calcaneal Fracture with Primary Subtalar Arthrodesis

A 27-year-old male sustained a closed Sanders IV calcaneal fracture after falling ten feet from a ladder. The patient presented with significant edema, but there were no fracture blisters, and the patient has a positive wrinkle sign laterally over the hindfoot and ankle. Marked bruising is present medially, laterally, plantarly, and going up the leg. The patient's light touch is intact over the toes. The patient can actively flex and extend their toes. The patient's calf is soft and supple.

Radiographic Examination

X-ray (Figure 1 (A–C)) and CT scan (Figure 2 (A–C)) showed a Sanders IV joint depression fracture. There was significant comminution involving the lateral wall blowout, varus in shortening of the calcaneal tuber as well as fracturing of the sustentaculum. The sustentaculum appeared to be in a constant position. There were not any other obvious fractures or dislocations.

Surgical Technique

The patient was brought to the operating room and placed on the operating table in the supine position. Following application of a general anesthetic and tourniquet, an incision was made through skin and superficial subcutaneous tissues cauterizing visible bleeders. Careful dissection was completed through compromised soft tissues, to the level of the peroneal tendon sheath, which was opened allowing for retraction of the peroneal tendons out of the operative field including the subcutaneous flap and the sural nerve. At this point in time, the comminuted lateral wall, that had blown out, was gently freed up allowing for direct visualization into the posterior facet. Hematoma and fibrous tissue were cleared out of the sinus tarsi and two pins

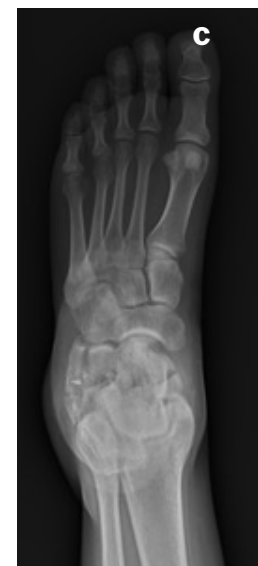
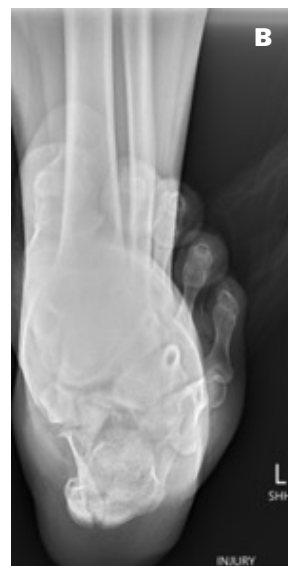
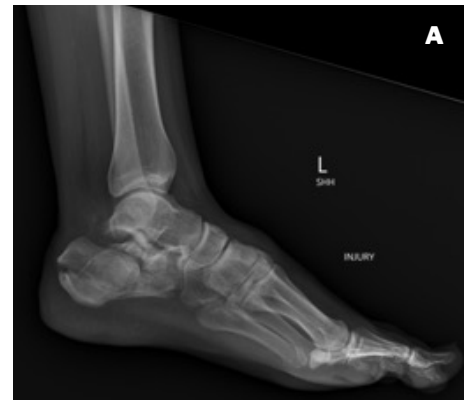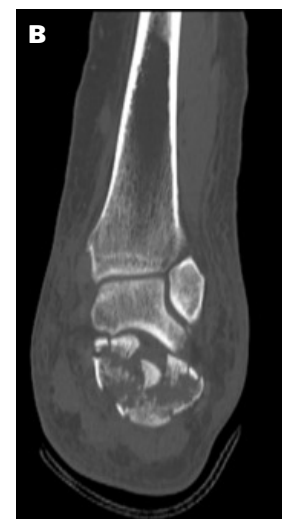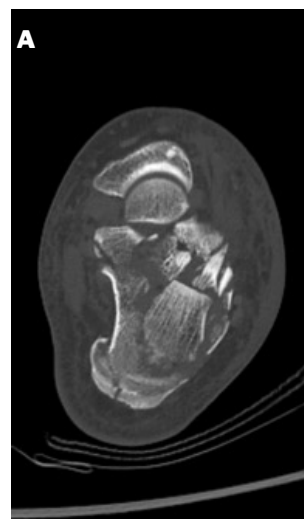Figure 1 (A–C): Injury films. **A.** NWB lateral view shows displaced, comminuted, joint depression calcaneal fracture with a tongue variant. **B.** NWB axial view shows comminuted tuberosity with lateral wall expansion. **C.** NWB AP foot view shows extension into calcaneal cuboid joint and lateral wall expansion



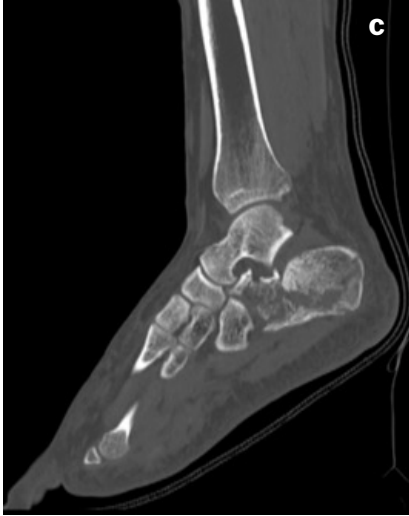

Figure 2 (A-C): CT Scan of fracture. **A.** Axial view depicting severe comminution of the posterior facet of the subtalar joint and lateral wall blowout. **B.** Coronal view **C.** Lateral view.

were placed in the posterior tuberosity going from posterior to anterior along the inside portion of the medial wall. A Schanz pin was placed in the posterior tuberosity allowing for reduction of the posterior tongue fragment, reducing it out of varus and restoring the height. The position was confirmed and reduction on AP and lateral C-arm and advanced the two pins and placed two more pins going from the superior portion of the tongue fragment into the inferior portion of the tuber. Once this was completed the posterior facet was disimpacted, which was comminuted in greater than 4 pieces. There was significant articular cartilage shearing off in pieces that were completely denuded of its articular cartilage. The remaining articular cartilage was removed from the posterior facet calcaneal portion and from the talus itself. Good bleeding bone on both portions of the fusion site was achieved. Temporary fixation was then completed across the posterior facet. AP, lateral and Broden C-arm views were captured, showing excellent restoration of height, and good restoration of the contour. The respective joint surfaces were microfractured and two 5.5 mm Monster® Hindfoot screws were placed with washers (one into the neck and one into the body of the talus) to fuse the subtalar joint.

The next portion of the procedure focused on addressing the anterior process anteriorly. The fracture was made up of at least four pieces which were pieced together and provisionally fixated. A Gorilla® Sinus Tarsi Calc Fracture Plate was placed across the anterior fractures and fixated using 3.5 mm locking screws, two anteriorly and two in the posterior facet. AP, lateral, and Braden's view radiographs (Figure 3 A-C) were captured as well as calcaneal axial views, demonstrating reduction and the fusion construct. The body defect was packed with the cancellous chips, and the sinus tarsi with the above-stated V9-FC+™ bone graft and proceeded to close in anatomic layers.

Post operative protocol

At 12 weeks, radiographic signs of healing across the subtalar joint were shown and the patient reported decreasing pain at the fusion site. There was radiographic evidence of trabeculation across the subtalar joint and consolidation of the calcaneal fracture with normal sagittal plane alignment. (Figure 4 A-B). The patient was seen again at 5 months and radiographs demonstrated maturation of the subtalar arthrodesis with maintenance of alignment (Figure 5 A-C). The ostia of the fracture appeared to have healed well as alignment appeared to be near anatomic with a normalized Bohler's angle. The avulsion fracture showed healing and there was no arthritis at the calcaneocuboid joint.

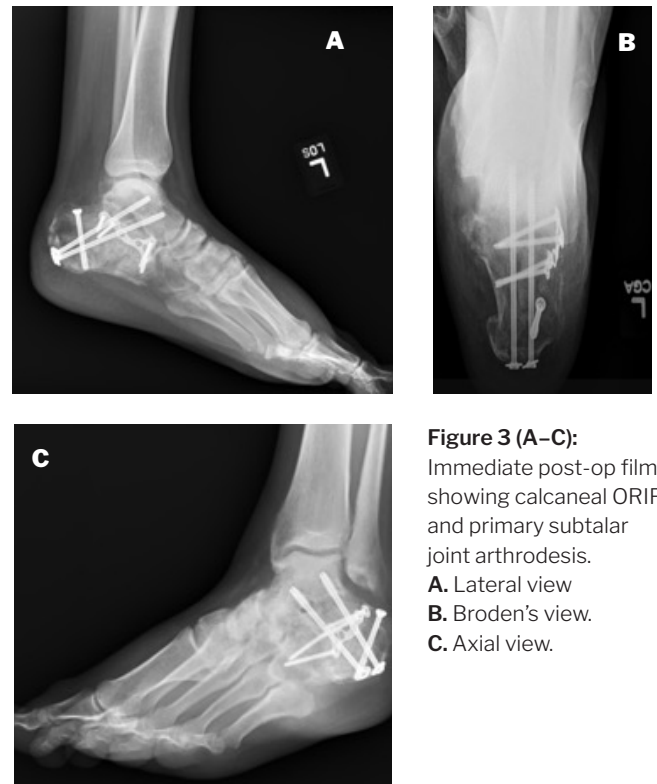

Figure 3 (A-C): Immediate post-op films showing calcaneal ORIF and primary subtalar joint arthrodesis. **A.** Lateral view **B.** Broden's view. **C.** Axial view.

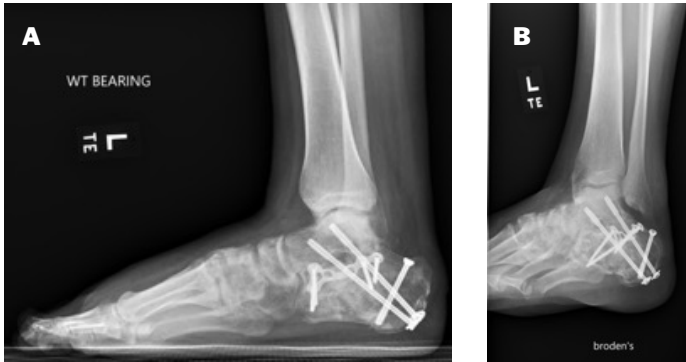


Figure 4 (A-B): X-rays at 3 months post op. Evidence of trabeculation across the subtalar joint and consolidation of calcaneal fracture. Note maintenance of normal talar sagittal plane alignment. **A.** Lateral view. **B.** Broden's view

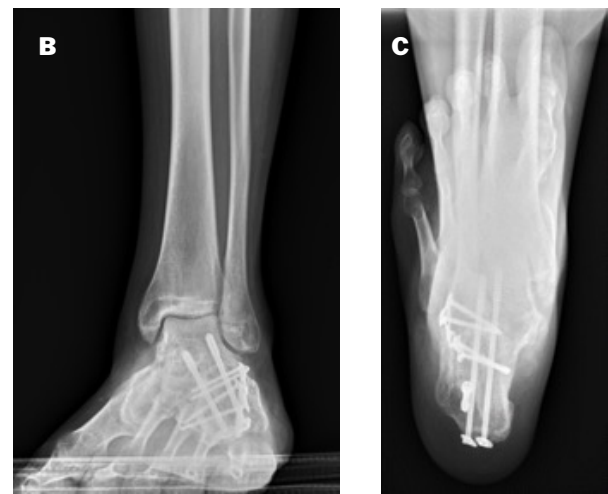
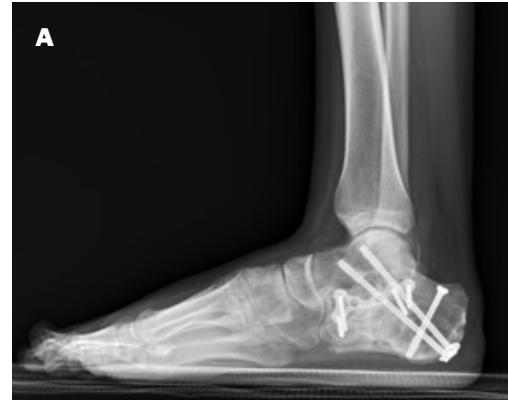
Figure 6 (A-C): X-rays at 10.5 months post-op depicting maturation of the subtalar arthrodesis with maintenance of alignment. **A.** Lateral view. **B.** Broden's view. **C.** Axial view.

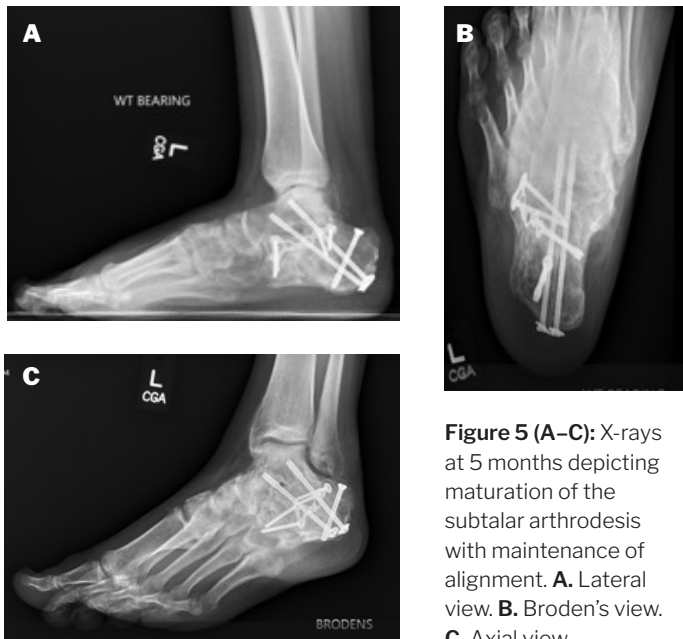


Figure 5 (A-C): X-rays at 5 months depicting maturation of the subtalar arthrodesis with maintenance of alignment. **A.** Lateral view. **B.** Broden's view. **C.** Axial view.

CASE 2: TTC Fusion

A 43-year-old male with dropfoot secondary to a traumatic brain injury presented for a second opinion. Three years prior to this visit, the patient underwent tibiotalar calcaneal fusion with a hindfoot fusion nail. The patient noted that they were pain free for two years following the original surgery and then started having swelling, pain, and instability of the hindfoot. The patient underwent a second surgery to have one of the screws removed from the nail which had become loose. However, the patient continued to have pain and further hardware loosening as well as radiographic evidence of non-union and lucency around the hardware. Due to concerns of infection the original surgeon offered a below knee amputation. Upon presentation, the patient had no local or systemic signs of infection; however,

a septic non-union work up was undertaken. The patient had normal serologic markers. The radiographs showed subtalar and ankle joint non-union with an equinus malunion. AP and lateral view of the hindfoot showed viability of the talus and abnormal but present medial malleolus. It was confirmed that the nonunion of the ankle and subtalar joints was with associated hardware failure (Figure 1 (A-C)). The patient was counseled on available options and agreed to a revision TTC fusion, tibial osteotomy, and posterior tibial tendon release.

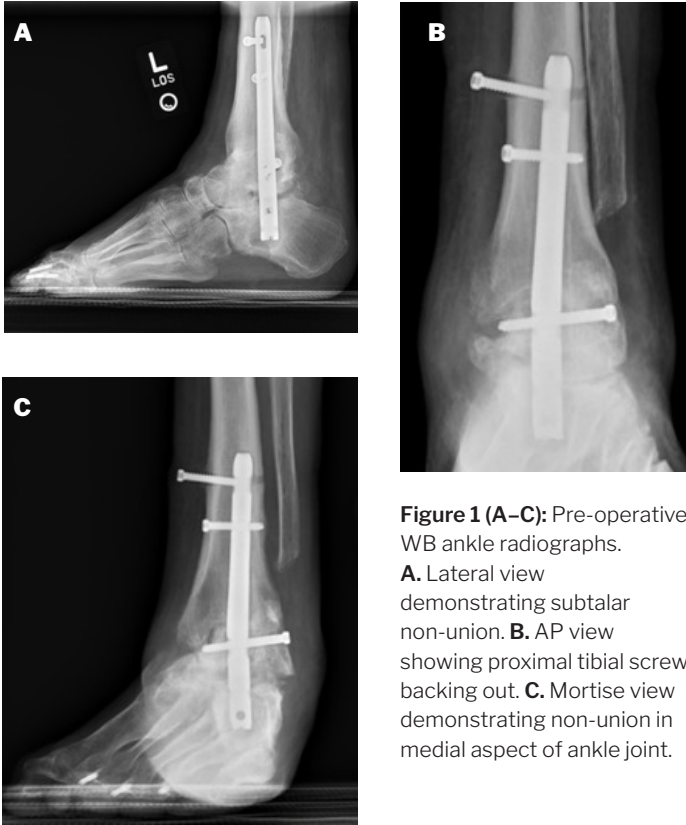

Figure 1 (A-C): Pre-operative WB ankle radiographs.

A. Lateral view demonstrating subtalar non-union. **B.** AP view showing proximal tibial screw backing out. **C.** Mortise view demonstrating non-union in medial aspect of ankle joint.

Surgical Technique

The patient underwent hardware removal with multiple bone biopsies and placement of antibiotic nail (vancomycin and tobramycin). The patient underwent 6 weeks of IV antibiotics. Once this was completed, the second stage of reconstruction was planned, and surgery was scheduled.

The patient was appropriately positioned, and an incision was made along the posterior medial border of the tibia. The posterior tibial tendon underwent a recession allowing for realignment of the talonavicular joint. The nail was then removed and the subtalar joint prepared using a fenestration drill. The subtalar joint was then packed with V92-FC+ to aid promoting fusion at the site. A supramalleolar osteotomy was performed on the tibia allowing for positioning in a more plantigrade position for fusion. A drill tip wire was placed to allow for drilling and sequential reaming of the tibia for the Phantom® ActivCore TTC Nail. Reaming was carried out to 12.5 mm and an 11.5 mm ActivCore Nail was inserted. Two interlocking calcaneal pegs were placed through the nail from posterior to anterior. Interlocking screws were then placed through the nail in the tibia. Once this was done, the dynamic compression portion of the nail was released. The nail was then released from the outrigger and an endcap was placed over the most distal portion of the nail. The remaining V92-FC+ was placed within the sinus tarsi around the ankle fusion site and

closure of the surgical site was completed.

Post operative protocol

The patient returned to clinic at two weeks and three non-weight bearing view of the ankle were taken showing coaptation of both the subtalar and ankle joint fusion sites (Figure 2 (A-C)). The distal tibial osteotomy showed excellent opposition and the nail remained countersunk below the level of the calcaneus. Stiches were removed and the patient was placed into a below-knee non-weight-bearing cast. The patient returned at nine weeks and reported that the patient had been ambulatory in his fracture boot with very little pain. Three weight-bearing views of the ankle as well as the tib-fib and foot films were captured. The radiographs demonstrated continued consolidation at the tibial osteotomy and progression of bony fusion across the subtalar joint (Figure 3 (A-C)). There were no signs of hardware loosening and/or stress around the implant. Rocker bottom shoes were recommended for the patient and a follow-up visit was scheduled for two months. The patient returned to clinic at five months post-op and weight-bearing films were captured demonstrating continued bone formation and no sign of stress around any of the hardware (Figure 4 (A-C)). Bony bridging across the anterior surface of the subtalar joint was more mature than posteriorly and the patient reported improved pain and increased activity. The patient was asked to return in six months. The patient returned at one-year post-op and weightbearing views of the ankle and tib-fib were taken showing continued consolidation along the ankle joint. There was some questionable joint lucency at the subtalar joint itself with no signs of nail loosening. The patient reported pain and activity had improved since the previous visit and the patient was advised to continue to schedule

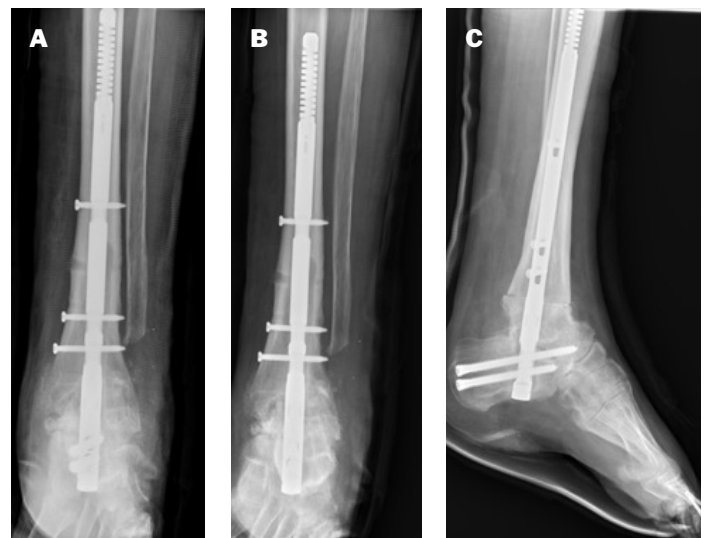


Figure 2 (A-C): Three NWB ankle radiographs post-op week two showing TTC fusion with tibial osteotomy. **A.** AP view **B.** Mortise view **C.** Lateral view

V92-FC+™ Cellular Bone Matrix

follow-up visits at six-month intervals to confirm maintenance and avoidance of any post-operative complications. Normal alignment parameters were maintained through the recovery with decreased pain at the fusion site clinically.

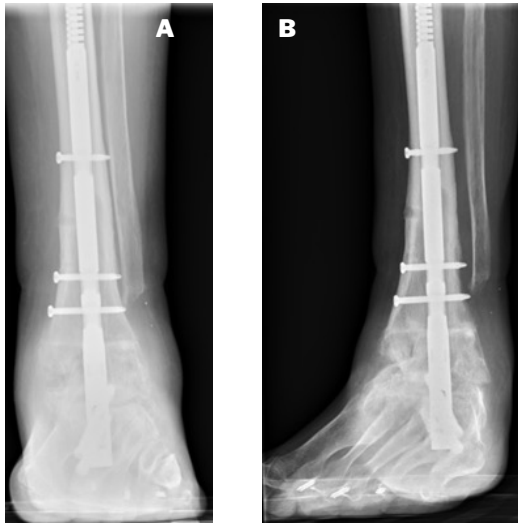


Figure 3 (A-C): Three WB ankle radiographs 3 months post op showing signs of fusion across the ankle and subtalar joints and union of the tibial osteotomy. **A.** AP view **B.** Mortise view **C.** Lateral view

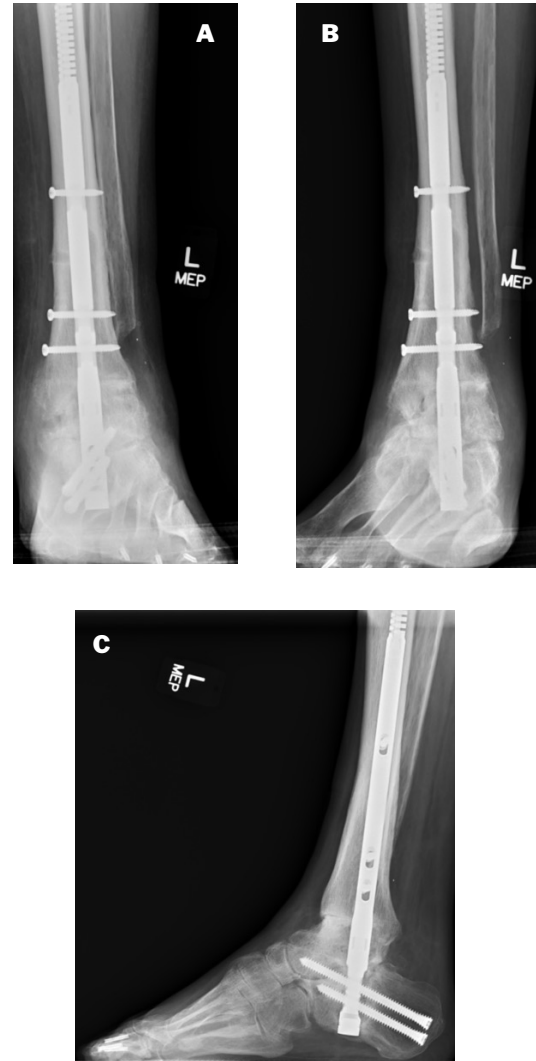


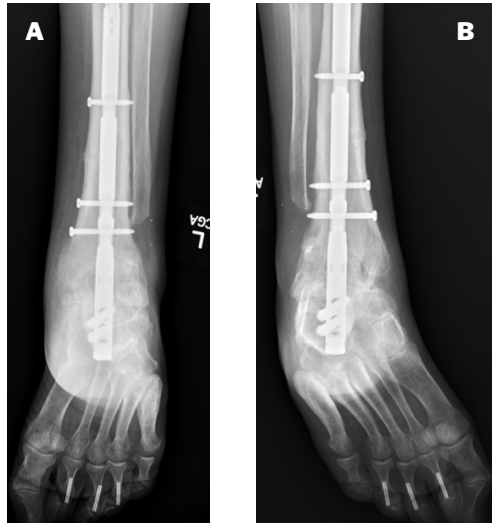
Figure 4 (A-C): Three WB ankle radiographs 5 months post op showing maturing signs of fusion across the ankle and subtalar joints and union of the tibial osteotomy. **A.** AP view **B.** Mortise view **C.** Lateral view

CASE 3: Triple Arthrodesis

A 69-year-old with syringomyelia presented with semi-reducible progressive equinovarus deformity of both lower extremities. Weight-bearing views of the right foot and ankle demonstrated significant sagittal plane cavus with the apex of the deformity at the level of the talonavicular joint with a relative normally aligned ankle (Figure 1 (A-C)). The patient had failed multiple attempts at bracing and desired surgical intervention. The surgical plan included an Achilles tendon lengthening, Steindler stripping, triple arthrodesis with osteotomy, posterior tibial tendon transfer and a dorsiflexion wedge osteotomy of the 1st metatarsal.

Surgical Technique

Attention was first directed to the posterior aspect of the leg confirming gastric soleus equinus. An Achilles tendon lengthening was performed using an 11 blade with hemisection performed at each level, leaving the Achilles tendon intact and achieving 10 degrees of dorsiflexion with the knee extended. Attention was then directed to the medial aspect of the foot and an incision was made at the junction of the plantar and medial skin exposing the abductor hallucis which appeared to be quite atrophied. A plane was created between the abductor hallucis, and the plantar fascia and the plantar fascia was released entirely medial to lateral relieving the contracture along the 1st ray. The flexor digitorum brevis (FDB) and quadratus



was removed from the CC joint. Following joint preparation, the hindfoot was placed into a slight valgus position reducing the subtalar joint into position for fusion. Paragon 28's V92-FC+ was added to the subtalar aid in promoting fusion at the site. The subtalar joint was then fixed using two Paragon 28 5.5 mm Monster® Hindfoot Headless Screws. Provisional fixation of the calcaneal cuboid joint was then removed and V92-FC+ added again to aid in promoting fusion at the site. A Paragon 28 Gorilla® Universal Dogbone Plate was used to fixate the osteotomy. V92-FC+ was applied to the TN joint which was then reduced into position and fixated using a 4.5 mm Monster® Hindfoot Screw from the distal aspect of the navicular into the midline of the talar neck and into the body. Screw fixation was augmented with a Paragon 28 Gorilla Universal Dogbone Plate. Stable alignment of the hindfoot had been achieved however the first

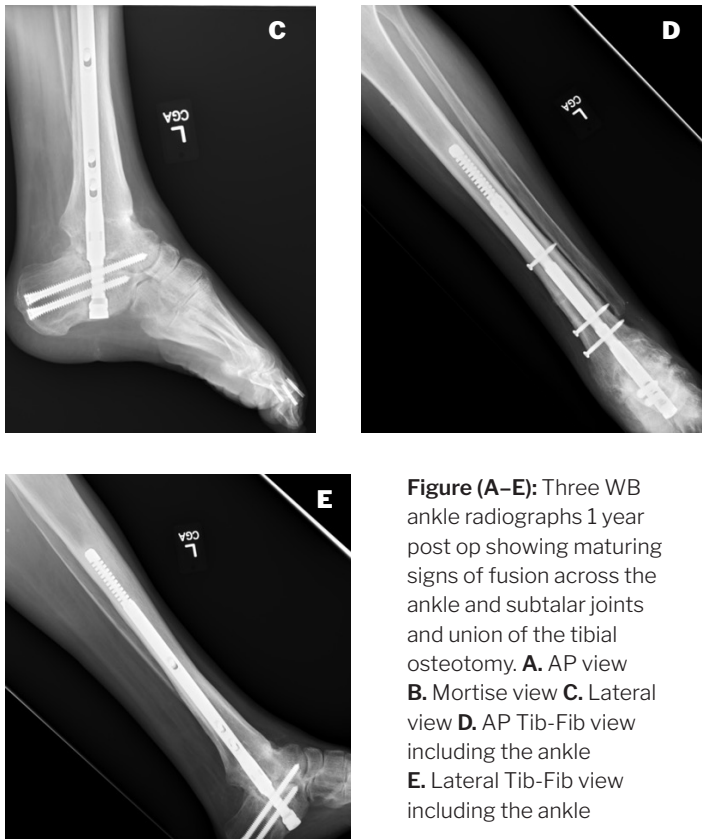

Figure (A-E): Three WB ankle radiographs 1 year post op showing maturing signs of fusion across the ankle and subtalar joints and union of the tibial osteotomy. **A.** AP view **B.** Mortise view **C.** Lateral view **D.** AP Tib-Fib view including the ankle **E.** Lateral Tib-Fib view including the ankle

plantar musculature were then released from the base of the calcaneus. Attention was then directed to the medial aspect of the foot and the posterior tibial tendon was released from its insertion site at the navicular. Removal of articular cartilage and subchondral bone was completed at the talonavicular (TN) joint. A fenestration drill was then used to prepare the TN joint. Attention was then directed laterally and direct access to the calcaneocuboid (CC) joint and subtalar joint was achieved. In similar fashion to the TN joint, the remaining cartilage and subchondral bone were removed. A small lateral base wedge

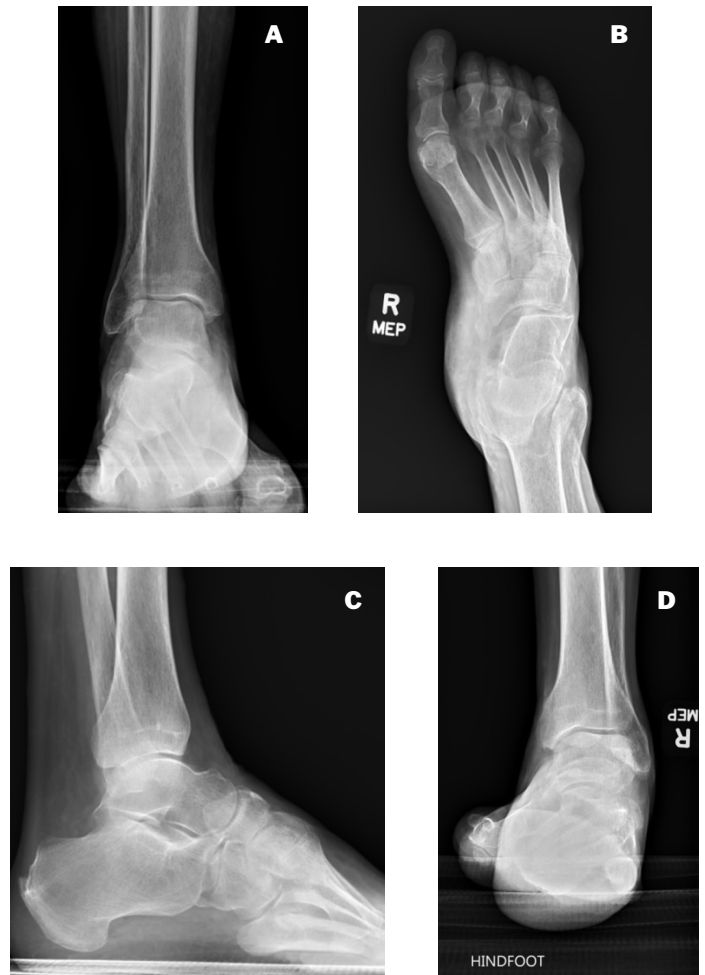

Figure 1 (A-D): Pre-operative WB films. **A.** Ankle AP showing normal ankle alignment. **B.** Foot AP showing adductovarus deformity of rearfoot and midfoot. **C.** Ankle/Foot Lateral showing cavus sagittal plane alignment. **D.** Hindfoot alignment view showing rearfoot varus deformity

ray had plantar flexed. An incision was made directly over the dorsal medial aspect of the 1st metatarsal at the junction of the proximal metaphysis and diaphysis. A dorsiflexor wedge on the metatarsal leaving a plantar hinge intact. The osteotomy was closed and temporarily pinned to confirm deformity correction. A Paragon 28® Universal 2-Hole Plate was used to achieve fixation of the osteotomy leveraging the eccentric proximal hole in the plate to achieve gain compression across the osteotomy site. Finally, the posterior tibial tendon was completed through the interosseous membrane and was fixated using a suture anchor. The patient was requested to return in two weeks for follow up.

Post operative protocol

X-Rays were collected at one-week post-operative showing maintenance of alignment (Figure 2 (A-C)). The patient returned a week later, and all incisions were clean, dry, and intact. All stitches were removed, and the patient was able to wiggle his toes and his sensation was at baseline. There was no tenderness along the calf or lower leg. The patient was converted to a cast and was asked to return in two weeks for a cast change and again in four weeks for additional non-weight-bearing x-rays of the right foot and ankle. The patient returned at three months post-surgery and weightbearing radiographs

of the right foot were taken showing good interval signs of fusion across the entirety of the fusion construct with stable hardware (Figure 3 (A-C)). His forefoot and midfoot alignment have improved significantly compared with preoperative films and the dorsiflexory wedge of the 1st metatarsal has consolidated. Meary's angle is nearly back to normal and there is a lucency in the intermediate cuneiform consistent with the tendon transfer. Continued maturation of the fusion site radiographically continued with absence of pain at the fusion site clinically. Normal alignment parameters were maintained at subsequent visits. At 14 months, radiographs were obtained demonstrating a solid arthrodesis through the entirety of the hindfoot with stable hardware throughout with evidence of a healed 1st metatarsal osteotomy (Figure 4 (A-C)). There were no signs of degeneration within the ankle and there is still a well-rounded lucency in the central cuneiform consistent with tendon transfer on his standing films. The dropfoot has done remarkably well and the patient is walking with a heel to toe progression.

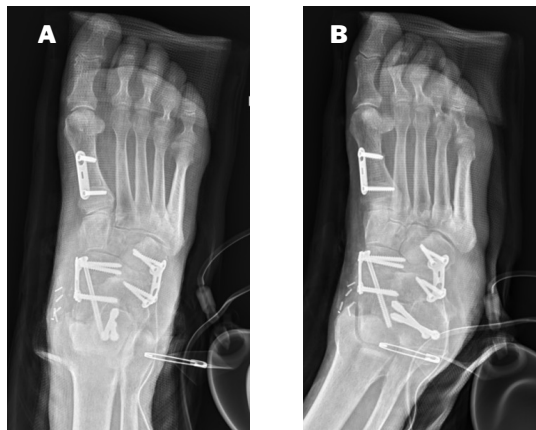


Figure 2 (A-C): Three NWB ankle radiographs post-op week 1 showing TTC fusion with tibial osteotomy.
A. AP view
B. Mortise view
C. Lateral view

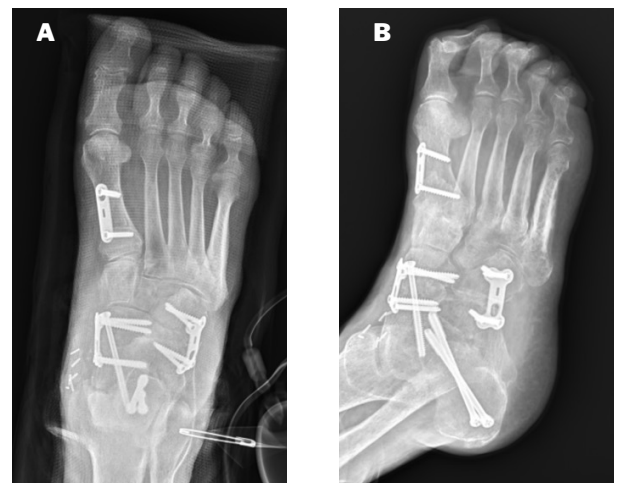
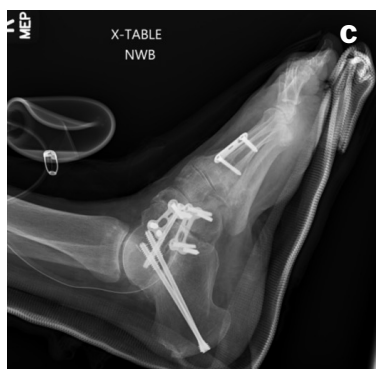
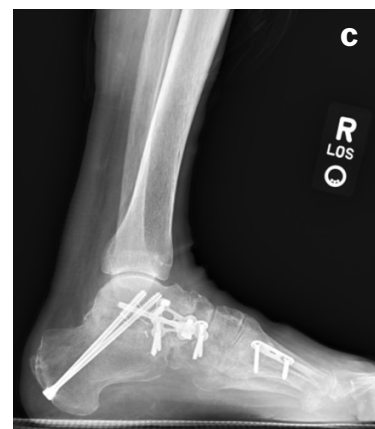
Figure 3 (A-C): Three WB ankle radiographs 3 months post-op showing signs of fusion across the ankle and subtalar joints and union of the tibial osteotomy.
A. AP view
B. Mortise view
C. Lateral view



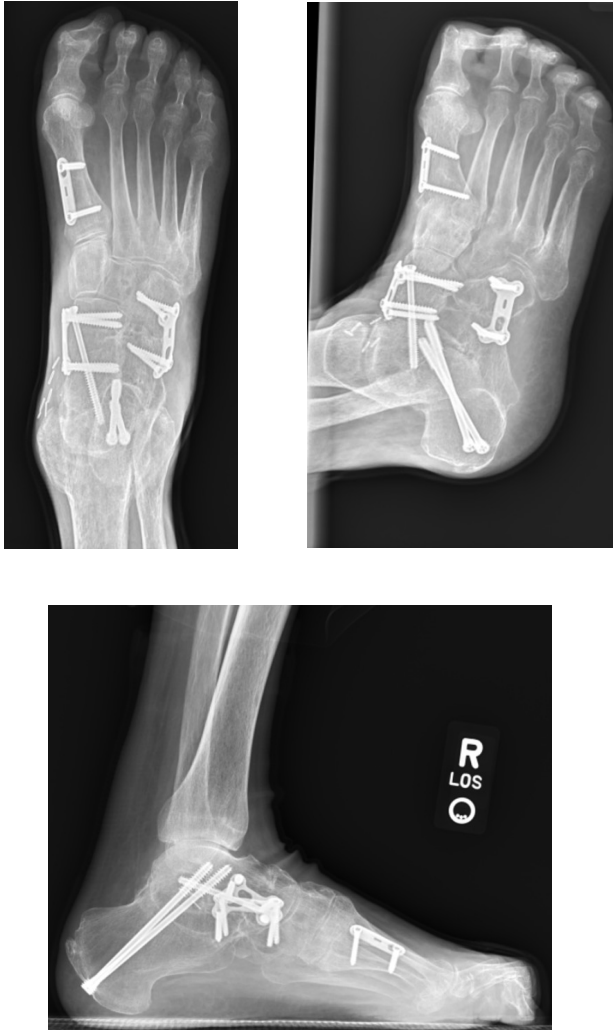

Figure 4 (A–C): WB X-rays at 14 months post op showing solid trabeculation across all 3 of the arthrodesis sights and the 1st metatarsal osteotomy. **A.** AP view **B.** Medial oblique view **C.** Lateral view

V92-FC+™ Cellular Bone Matrix
Monster® Hindfoot Screw System
Gorilla® Calc Fracture Plating System
Phantom® ActivCore Nail System
Gorilla® Universal Plating System

P51-WP-0001 Rev A
2023-11-07

Paragon 28®, Inc.
14445 Grasslands Dr.
Englewood, CO 80112 USA
(855) 786-2828

™Trademarks and ®Registered Marks of Paragon 28®, Inc.
© Copyright 2023 Paragon 28®, Inc. All rights reserved.
Patents: www.paragon28.com/patents



www.Paragon28.com